Mako Assisted Revision Total Knee Replacement

Alexander Caughran MD
Matthew Bullock DO, MPT
Micah Macaskill MD
Baylor Blickenstaff MD

Marshall Orthopaedics

Disclosures

None

Using the Mako Robotic-Arm System for Revision Total Knee Arthroplasty is currently OFF-LABEL

Objectives

- **Describe our surgical technique for Mako Robotic Arm Assisted Revision Total Knee Arthroplasty**

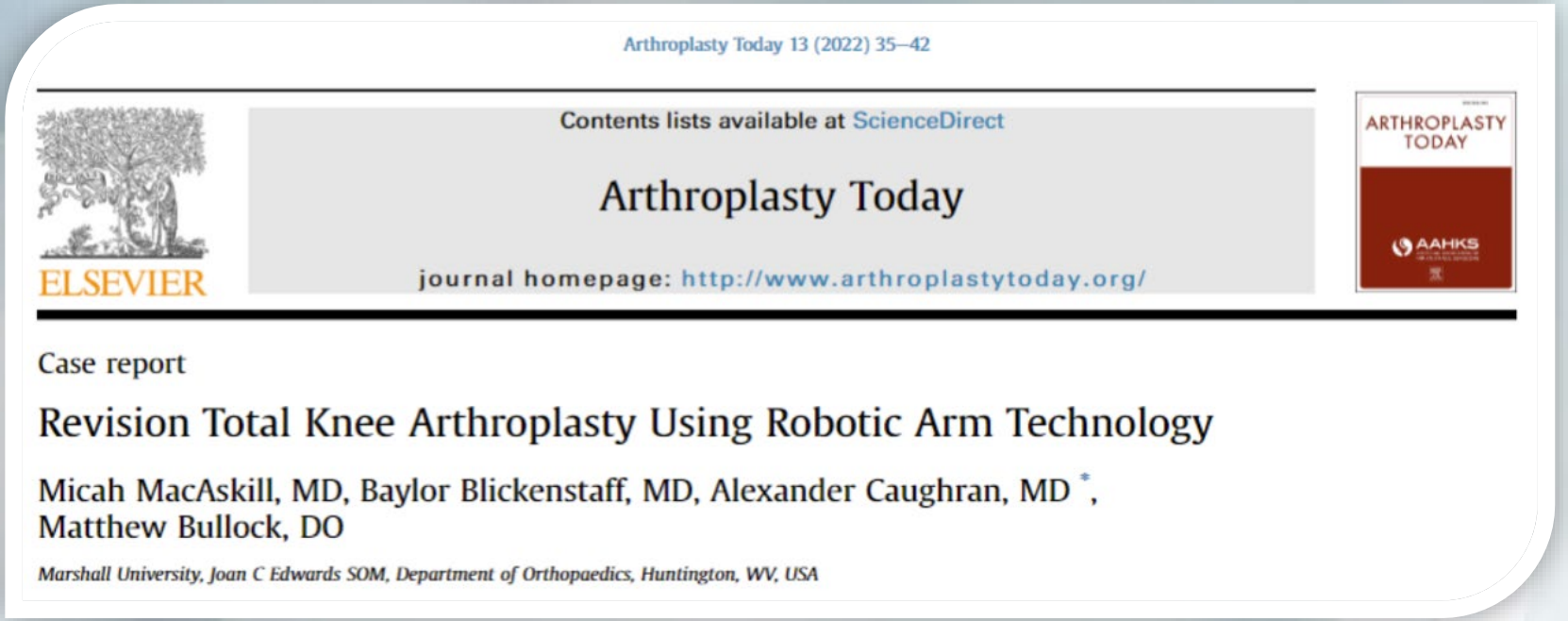

Arthroplasty Today 13 (2022) 35–42

Contents lists available at ScienceDirect

Arthroplasty Today

journal homepage: http://www.arthroplastytoday.org/

Case report

Revision Total Knee Arthroplasty Using Robotic Arm Technology

Micah MacAskill, MD, Baylor Blickenstaff, MD, Alexander Caughran, MD *, Matthew Bullock, DO

Marshall University, Joan C Edwards SOM, Department of Orthopaedics, Huntington, WV, USA

stryker
Mako
stryker
Mako
Mako

ROSA

VELYS
VELYS
DePuy Synthes

Why Robotic TKA?

- **Improved Accuracy and Precision**
  - *Deckey et al. Bone Joint J* 2021;103-B(6 Supple A):74–80.
- **Improved Joint Line Restoration**
  - *Agrawal et al. Arthroplasty* **4,** 6 (2022)
- **More Predictable Component positioning (UKA)/Alignment**
  - Bell SW. J Bone Joint Surg Am. 2016 Apr 20;98(8):627-35.
  - Song, EK. *Knee Surg Sports Traumatol Arthrosc* **19,** 1069–1076 (2011).
- **Improved Soft Tissue Balance**
  - Held MB. Arthroplast Today. 2021 Jan 30;7:130-134.

Khlopas et al: JOA 2018

Robotic-Assisted TKA

- **Long Term Ramifications?**
  - **Patient Outcomes**
    - Marchand KB et al. J Knee Surg. 2021 Jun 29
  - **Revision Rate?**
  - **Safety**
    - **Haptics**
    - **Radiation exposure**
  - **Cost?**

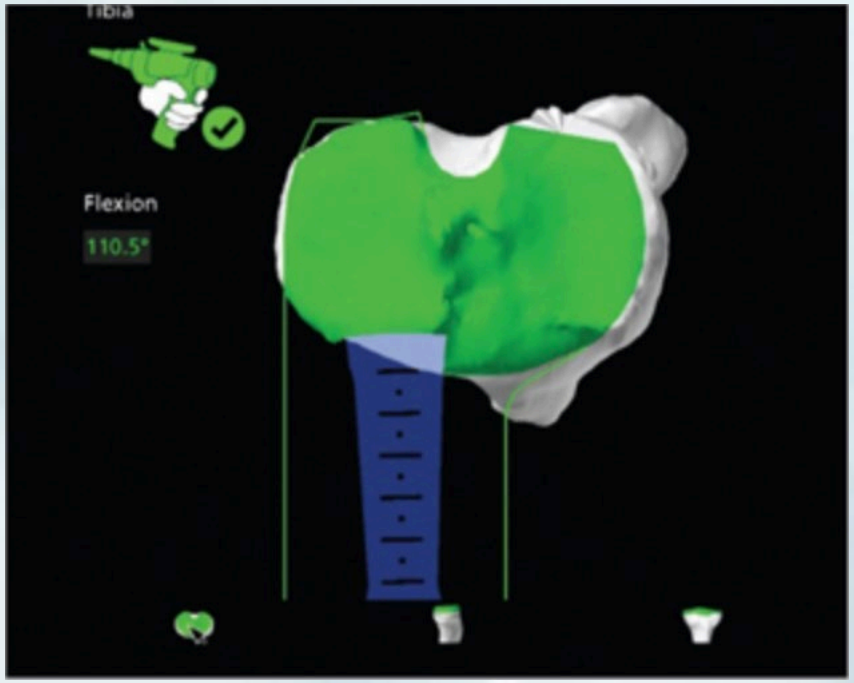

Robotic Conversion UKA to TKA

Case Rep Orthop. 2020; 2020: 4806987.
Published online 2020 Feb 12. doi: 10.1155/2020/4806987
PMCID: PMC7037895
PMID: 32099707

Expanding Robotic Arm-Assisted Knee Surgery: The First Attempt to Use the System for Knee Revision Arthroplasty

Dimitrios Kalavrytinos,[1] Christos Koutserimpas,[2,3] Ioannis Kalavrytinos,[4] and Konstantinos Dretakis[2]

Author information Article notes Copyright and License information Disclaimer

Knee Surg Relat Res. 2020; 32: 38.
Published online 2020 Jul 29. doi: 10.1186/s43019-020-00056-1
PMCID: PMC7389376
PMID: 32727605

Management of failed UKA to TKA: conventional versus robotic-assisted conversion technique

Andrew G. Yun,[1] Marilena Qutami,[1] Chang-Hwa Mary Chen,[2] and Kory B. Dylan Pasko[1]

Author information Article notes Copyright and License information Disclaimer

Case Example

61 y/o male chronic Left TKA PJI

- S/p Resection with antibiotic spacer
- ESR & CRP Normal
- Aspiration: No Growth

Segmentation & Implant Planning (1)

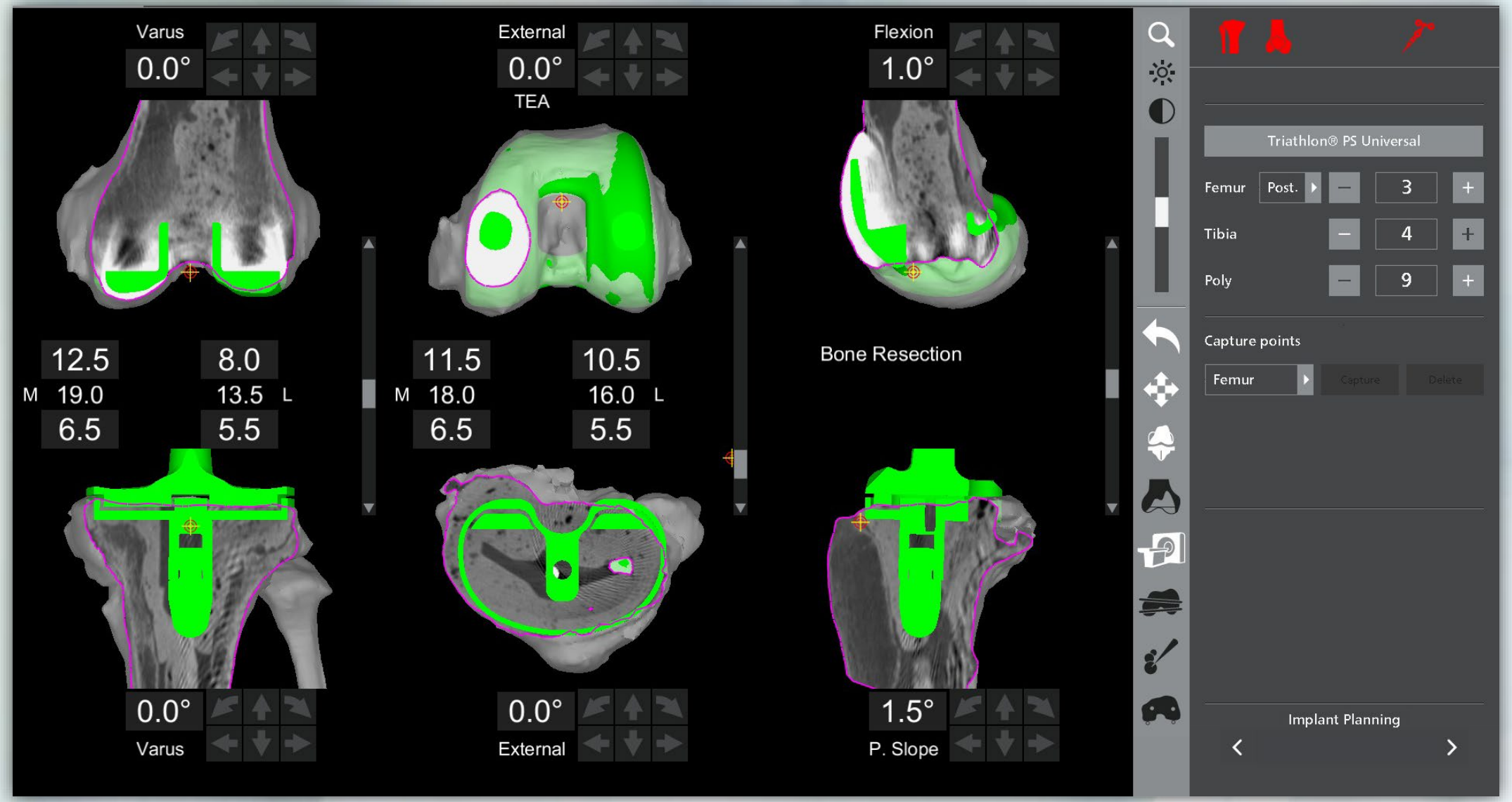

Find existing Bone-Implant Interface

Array Placement

Collect
Checkpoints
Hip Center
Medial & Lateral Malleoli

Femoral Array (Distal Femur Metaphysis)

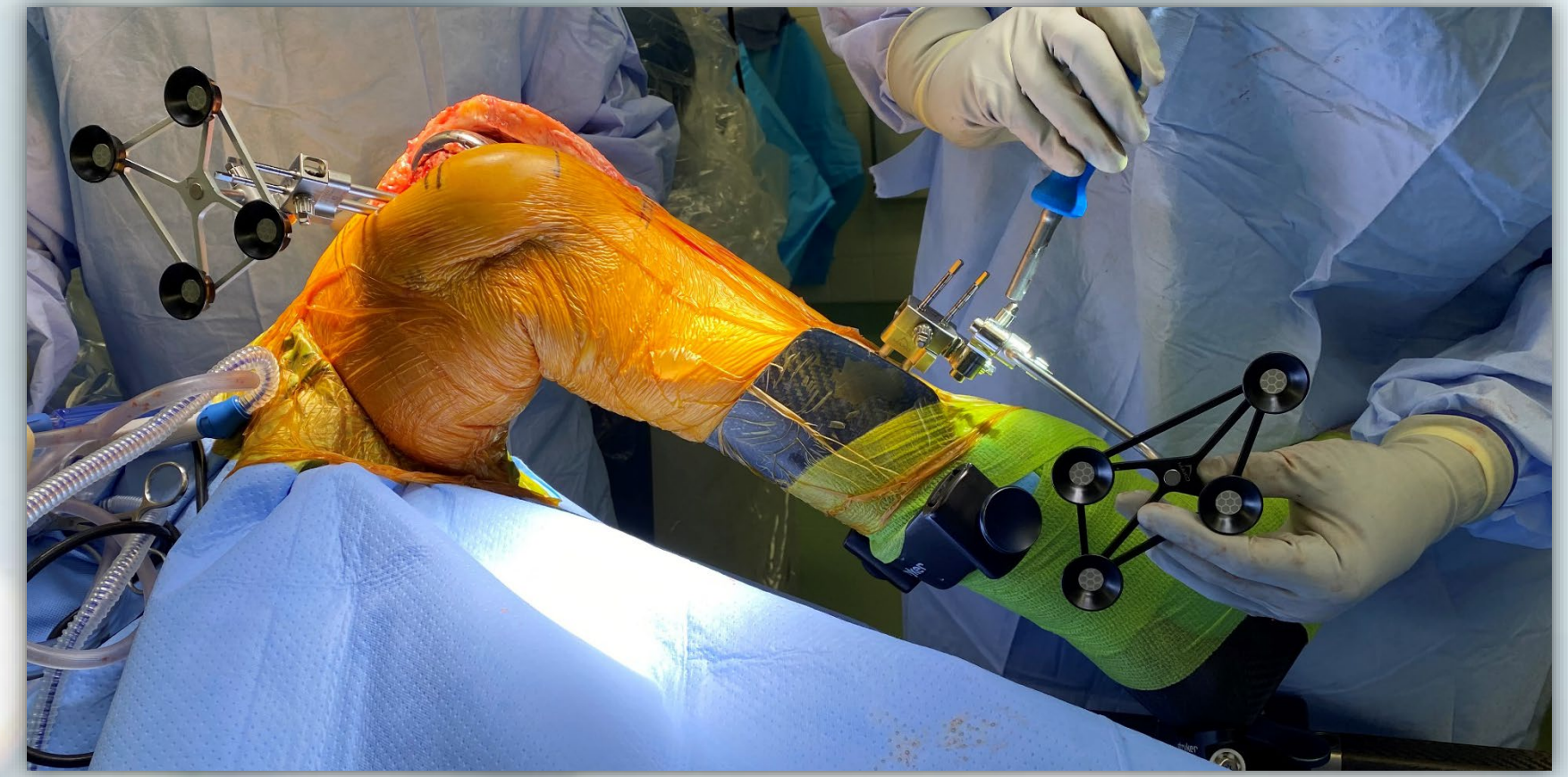

Tibial Array
(~160 mm from joint line)

Bone Registration

Need Accuracy
<0.5 mm

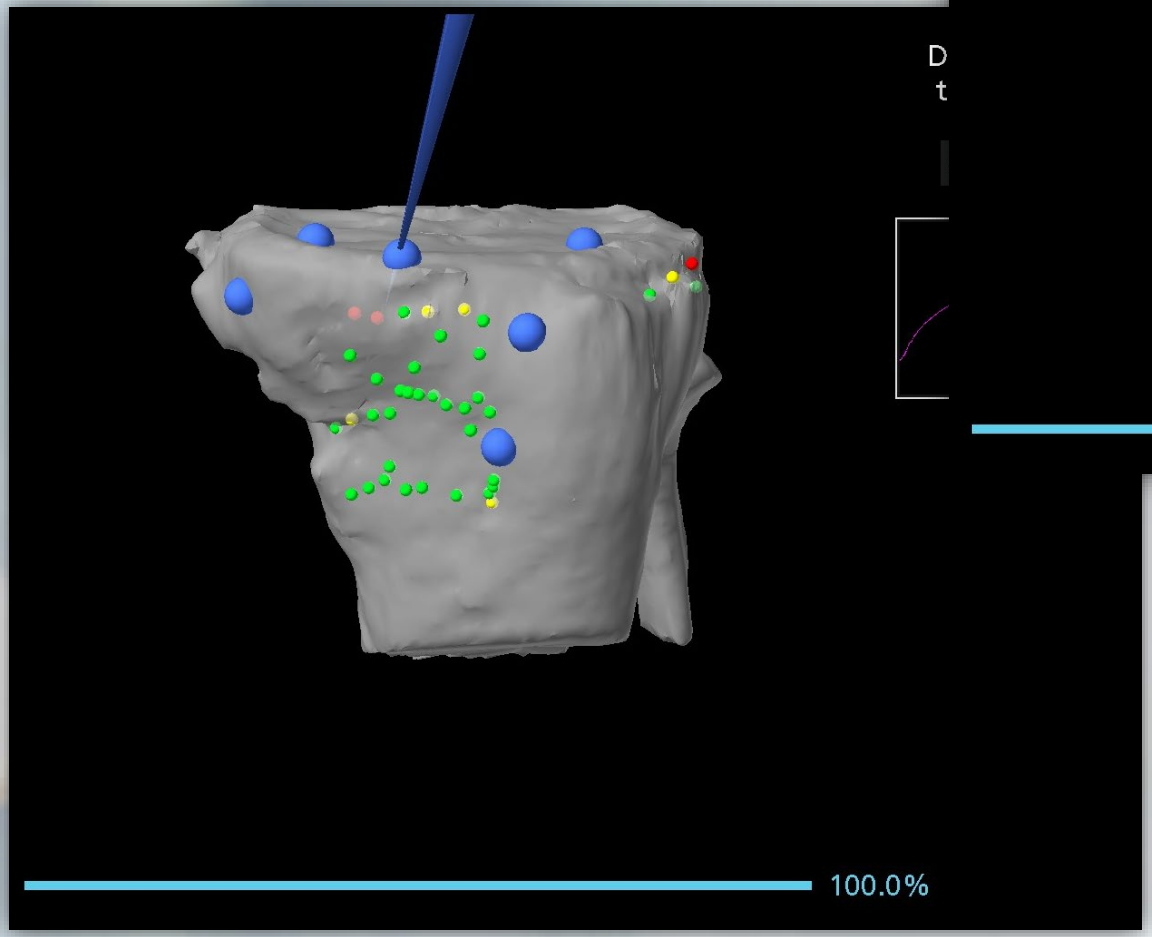

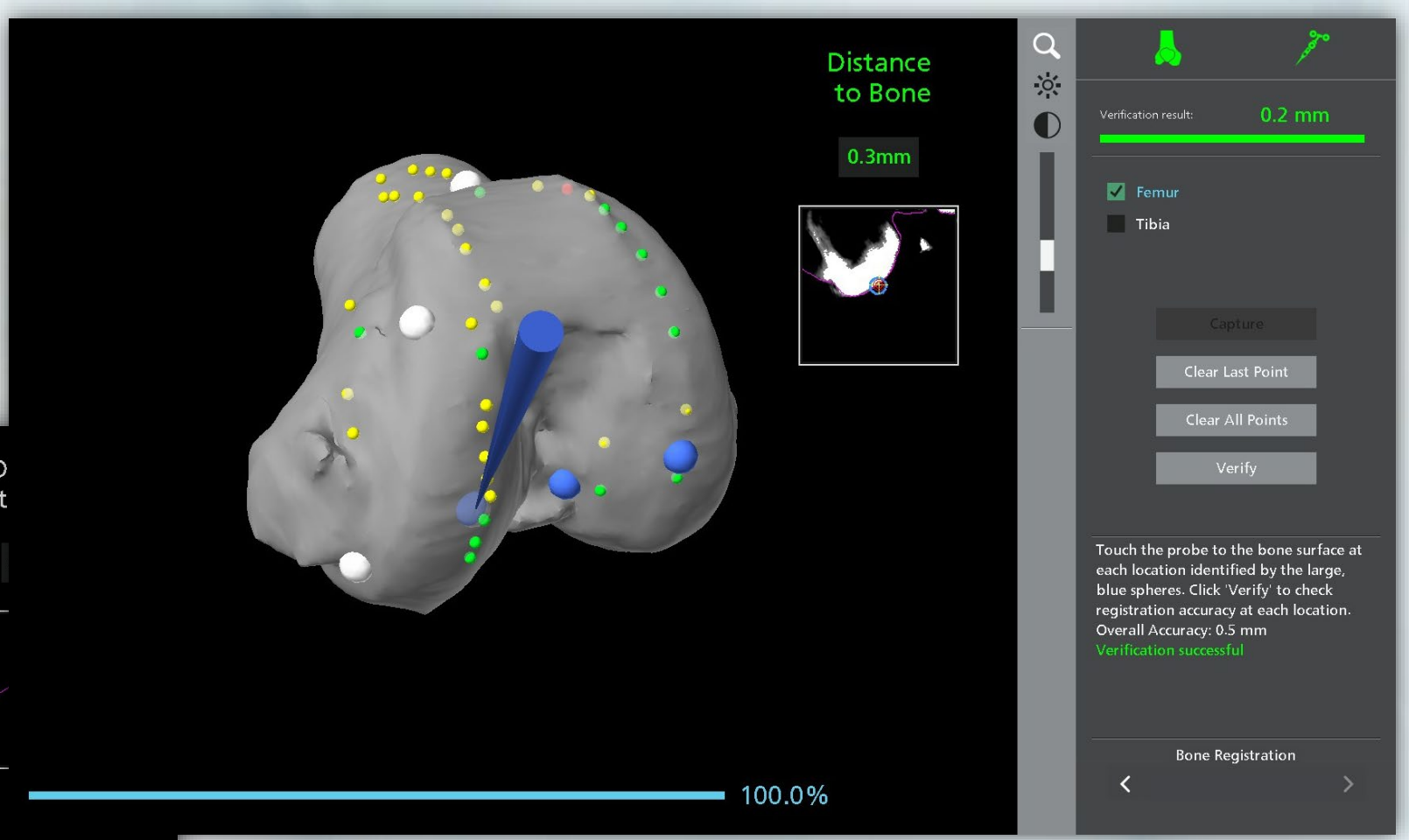

Most Reliable Points

Femur: Anterior & Lateral Metaphysis

Tibia: Plateau Rims & Anterior Metaphysis

Tibial Tubercle key for component rotation

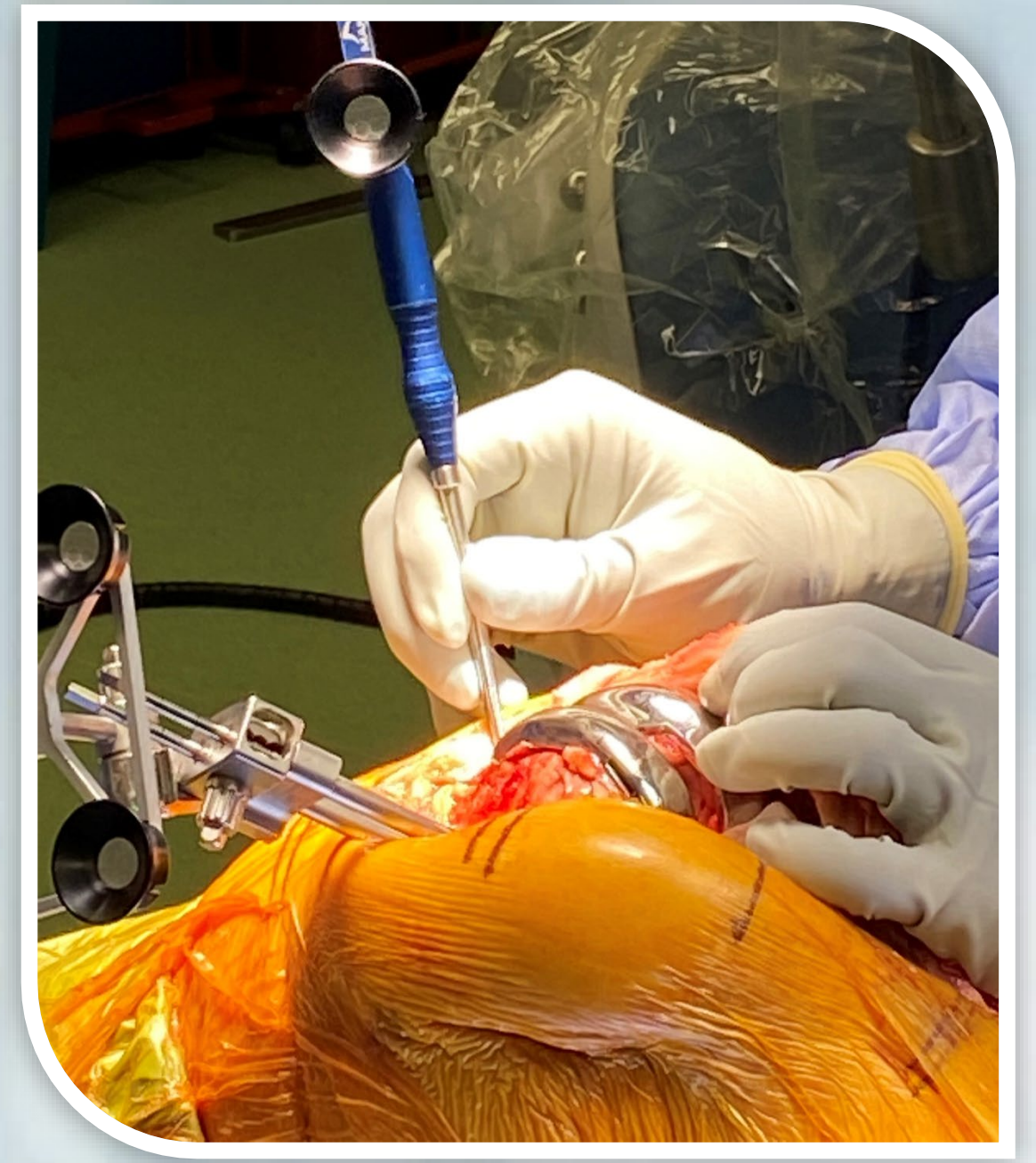

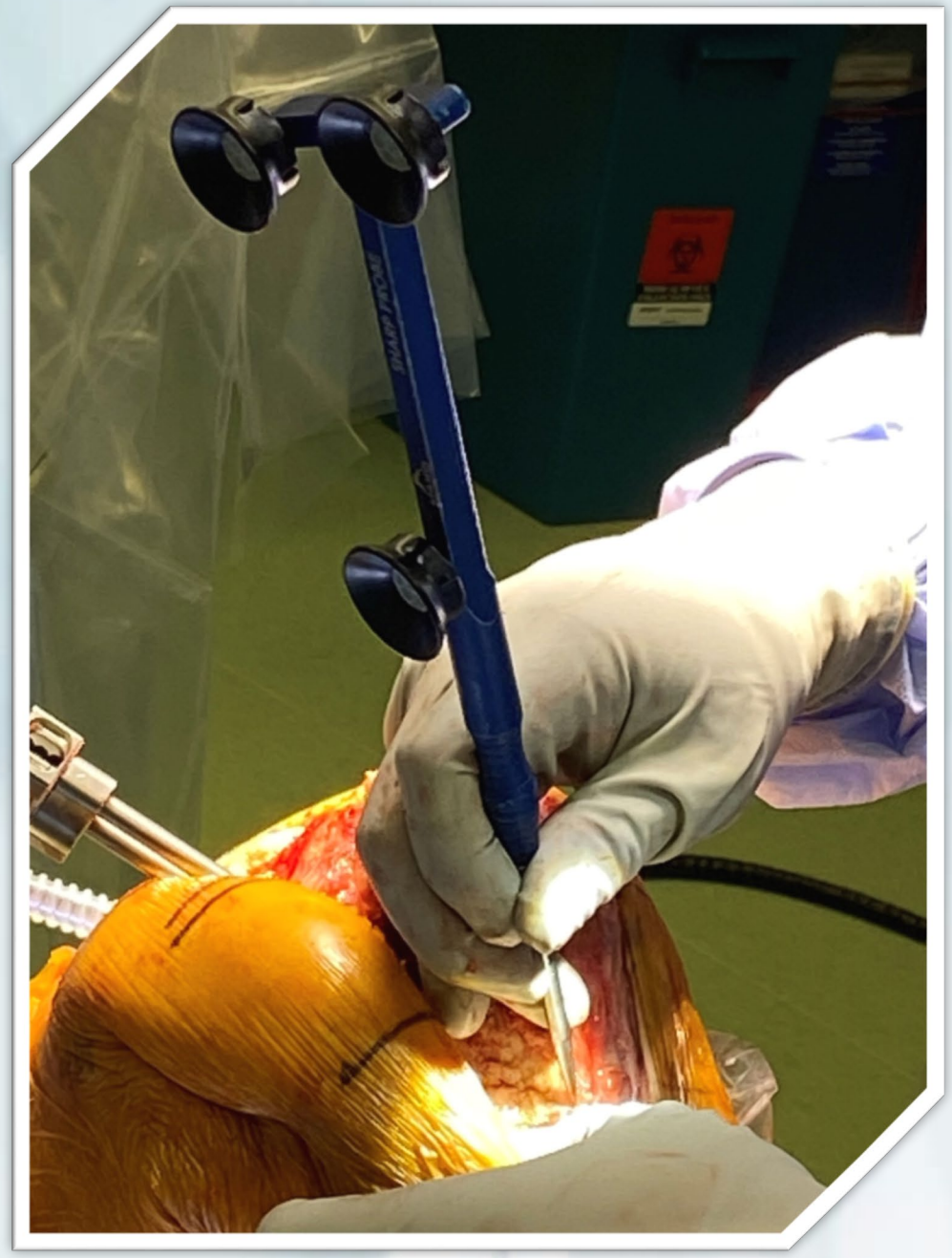

Removal of Existing Implants

Careful!!!

Preserve Bone

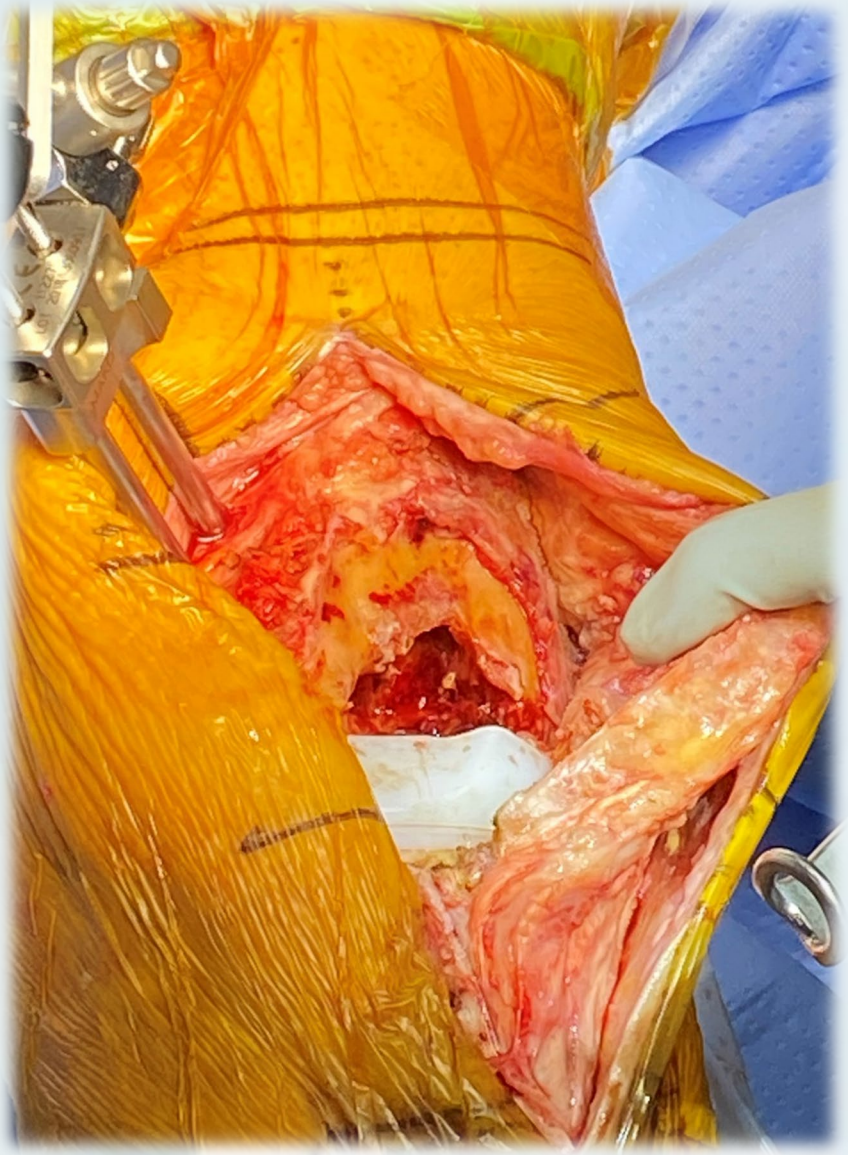

Ligament Assessment 1 (EXTENSION)

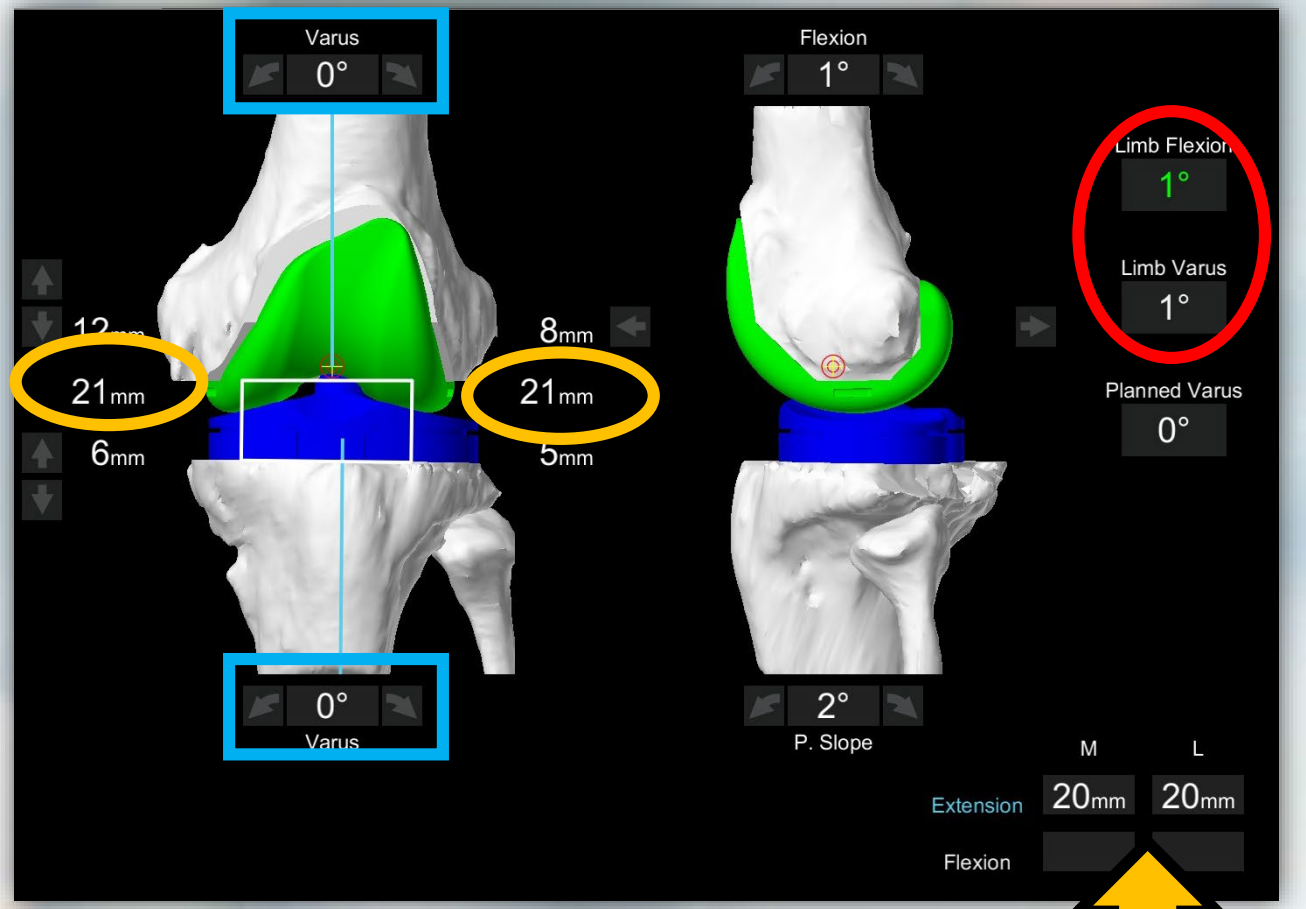

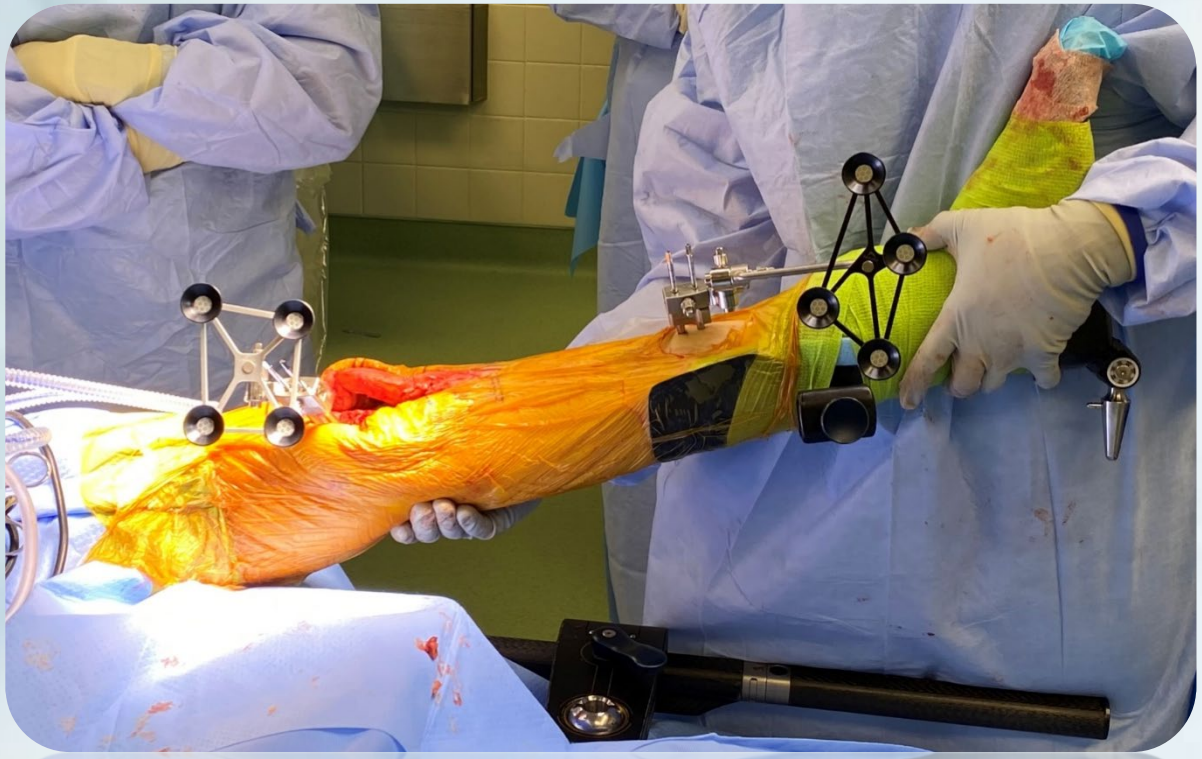

Ligament Assessment 1 (FLEXION)

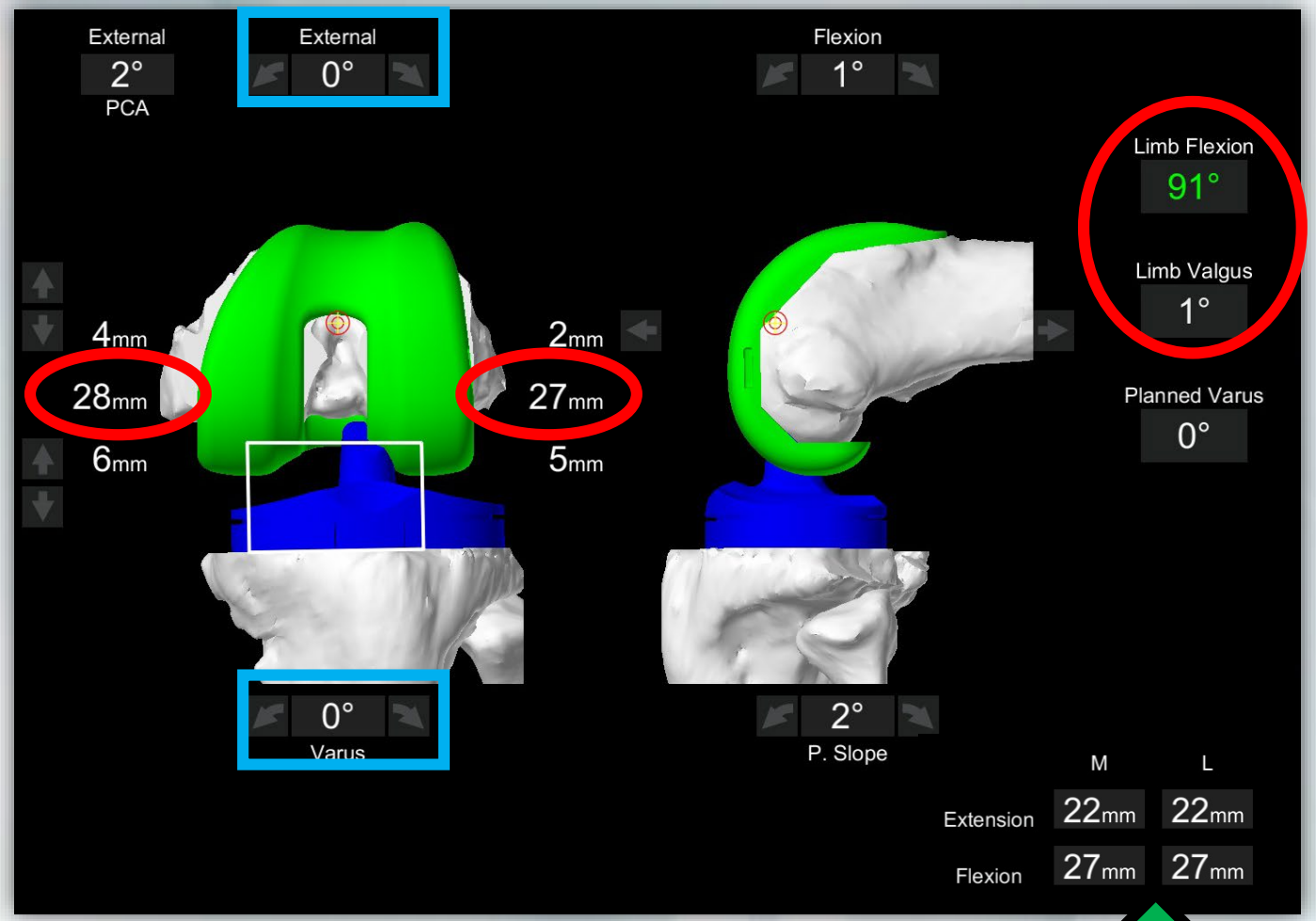

Fine Tuning

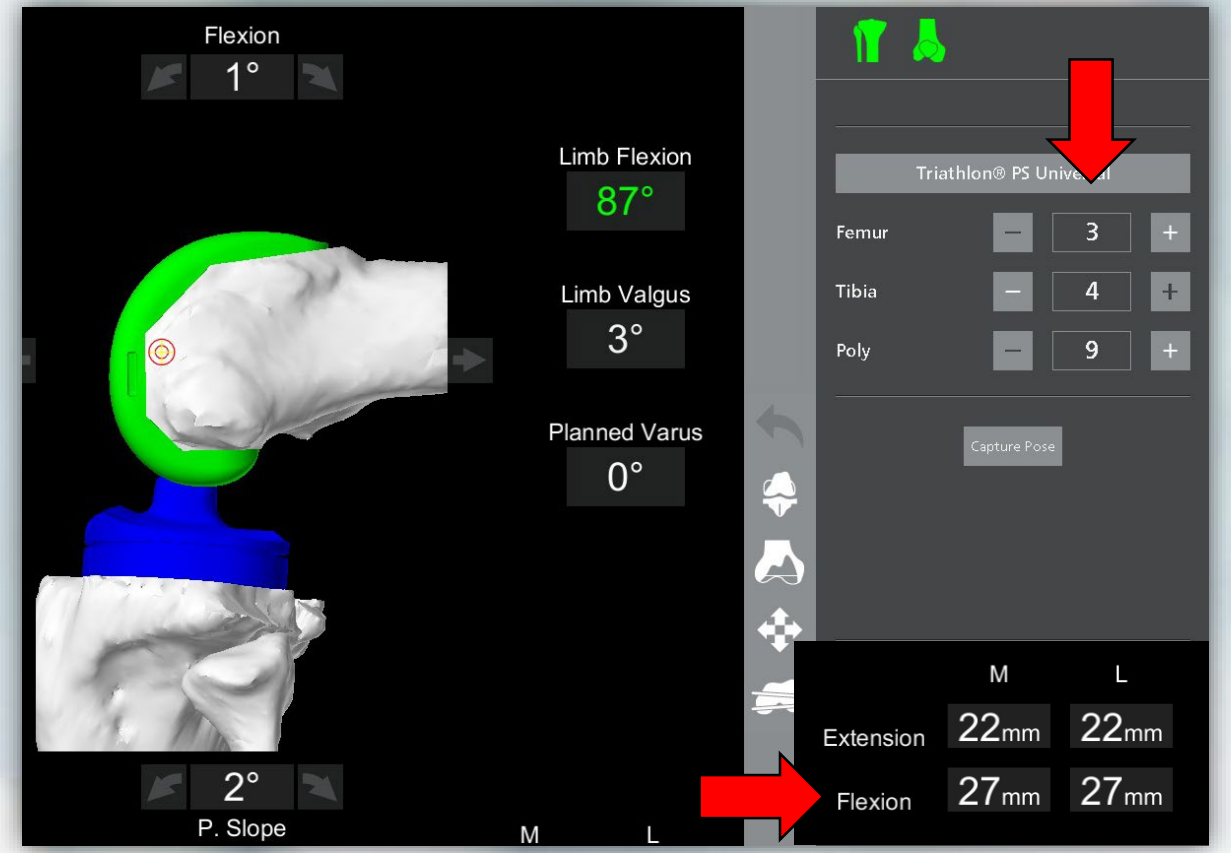

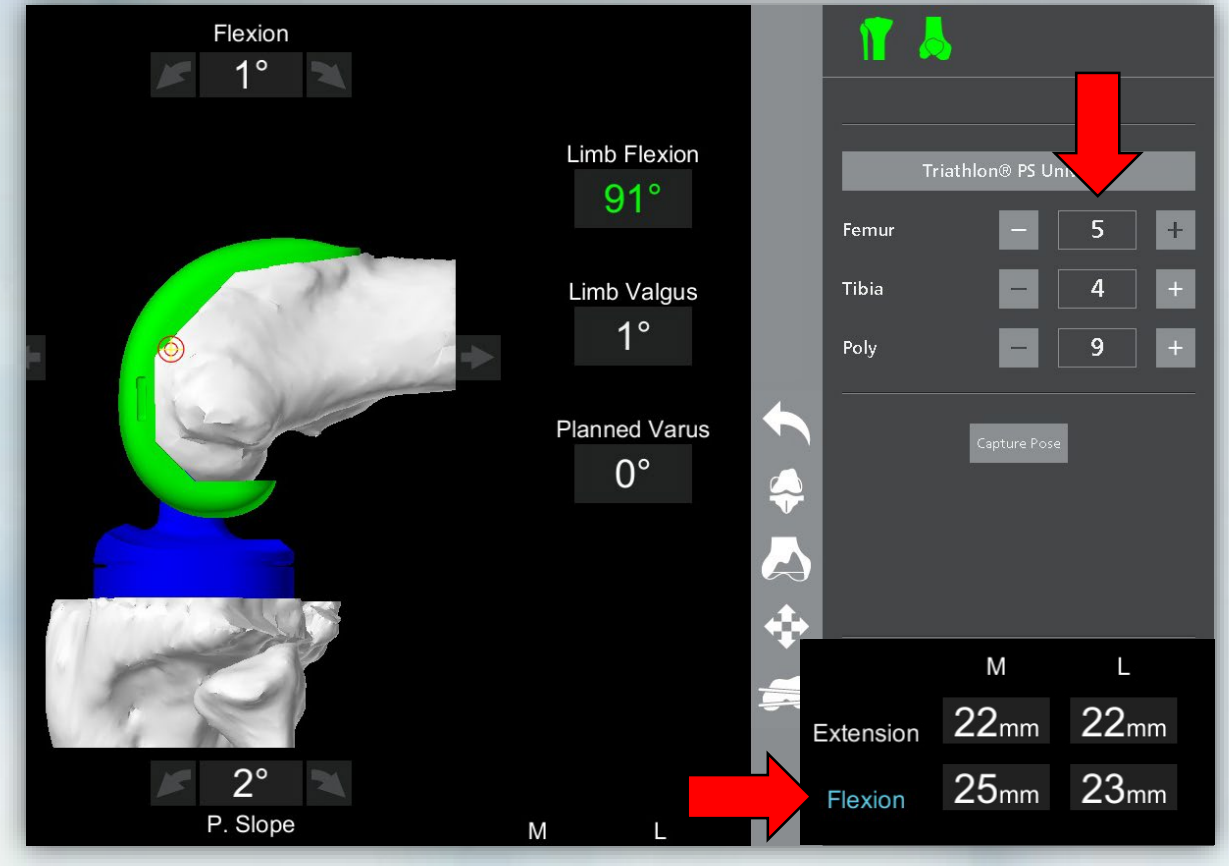

<u>CLOSE THE FLEXION GAP</u>: Upsize to 5 Femur and Posterorize Component

DO NOT NOTCH

Implant Planning 2 – Locate the Remaining Bone

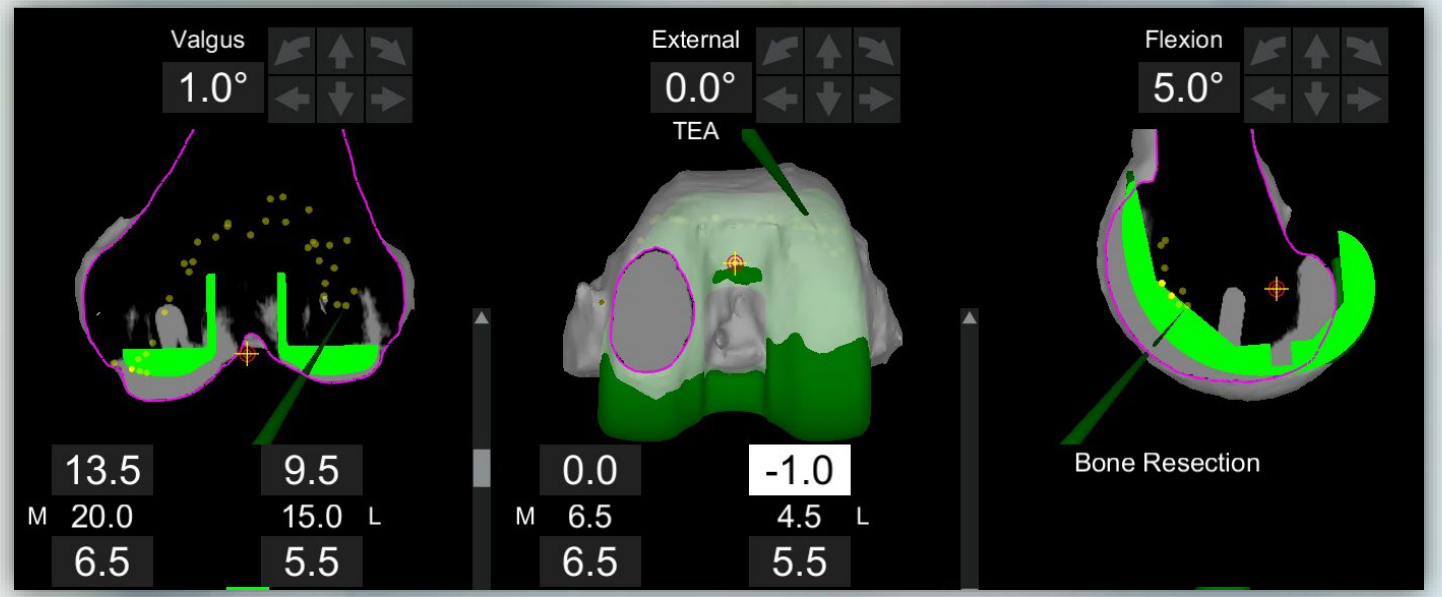

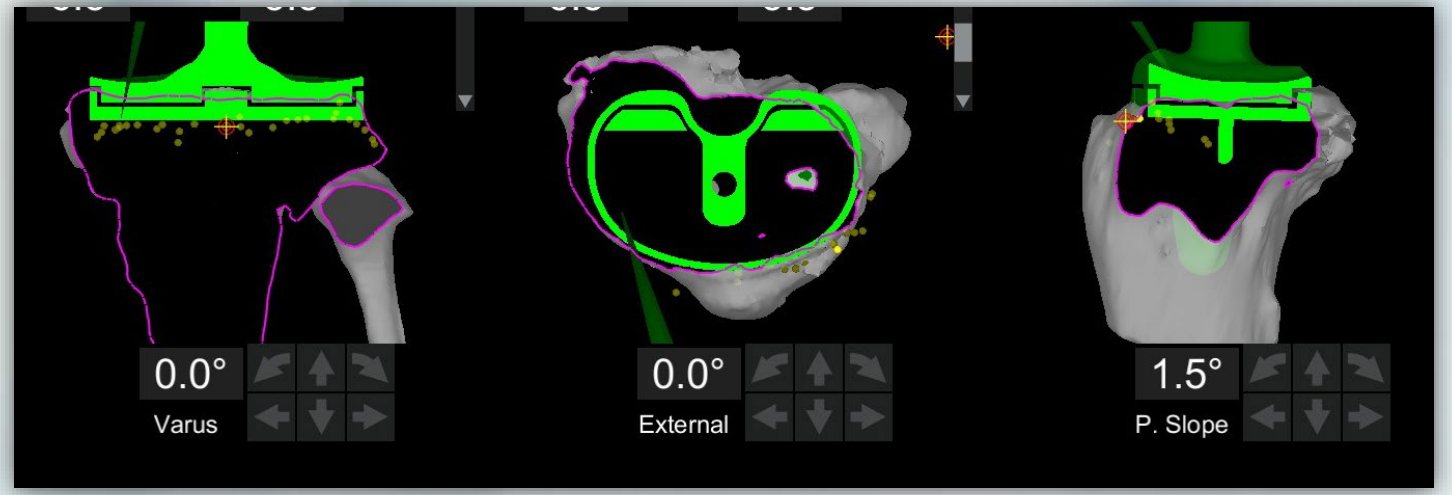

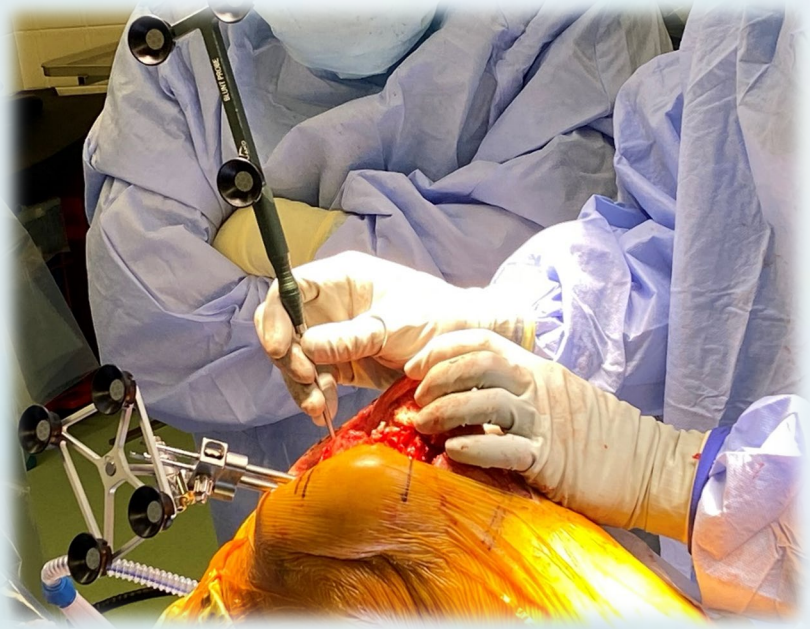

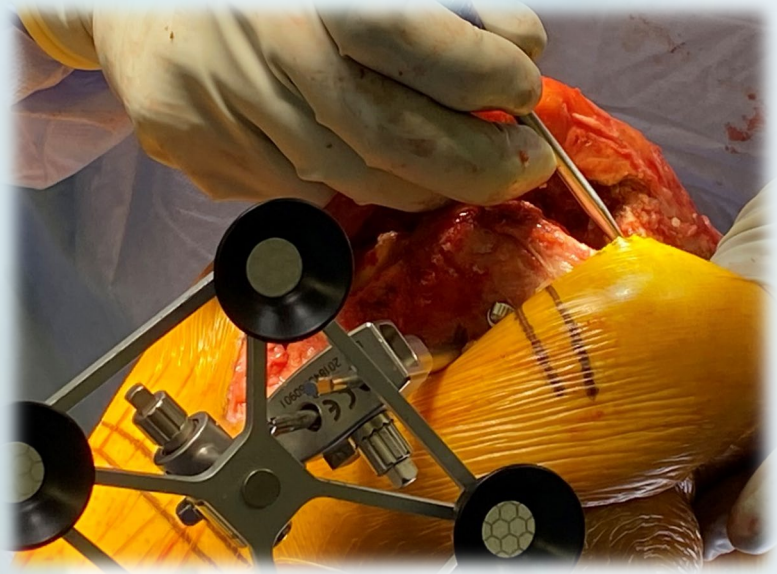

Fireflies

Locate the remaining bone
in all planes

**Refine Implant position to
rest within Yellow Fireflies**

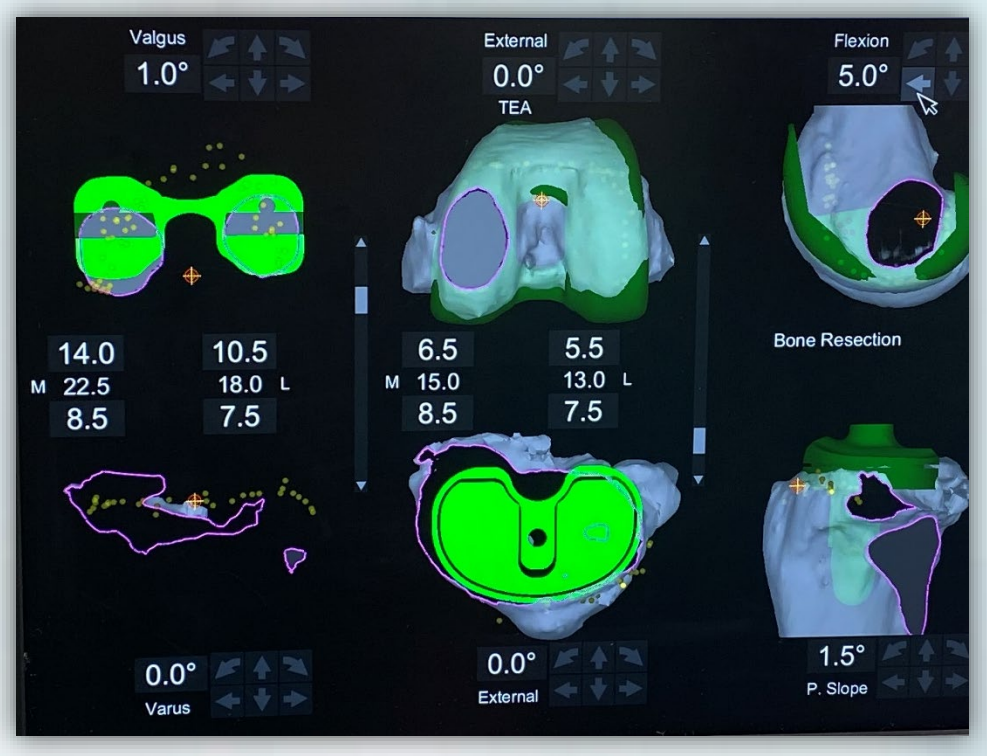

Bone Cuts

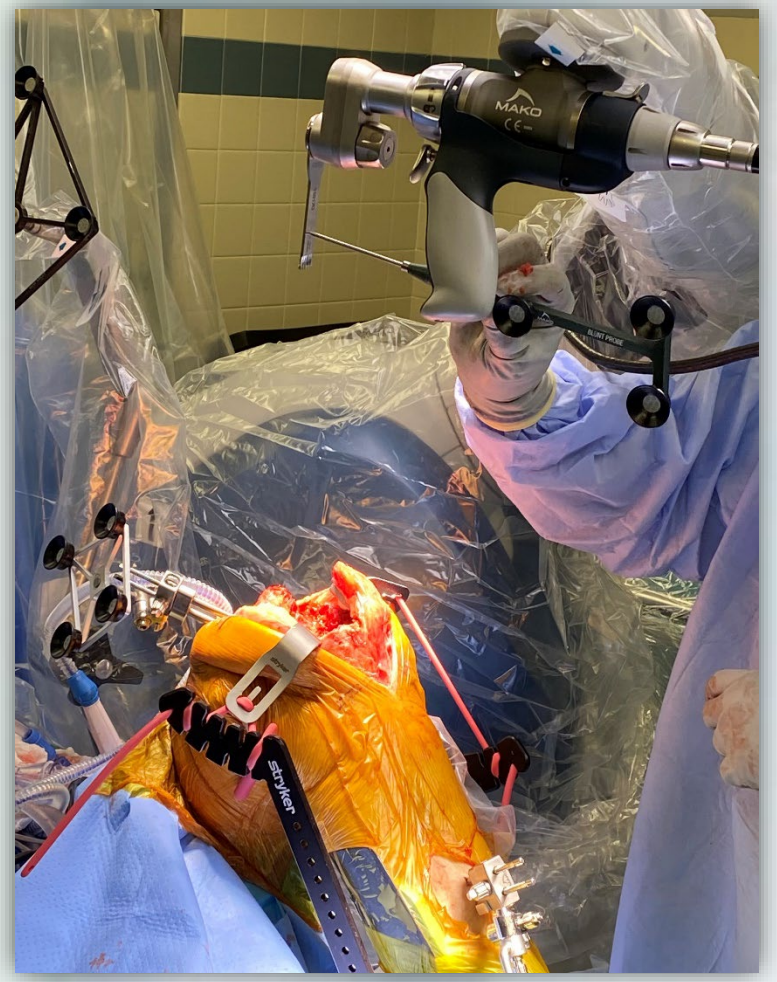

1 - Distal Femur

2 - Posterior Chamfer

----CHANGE BLADE----

3 - Proximal Tibia

4 - Anterior Femur

5 - Posterior Femur

6 - Anterior Chamfer

Augmentation (if necessary)

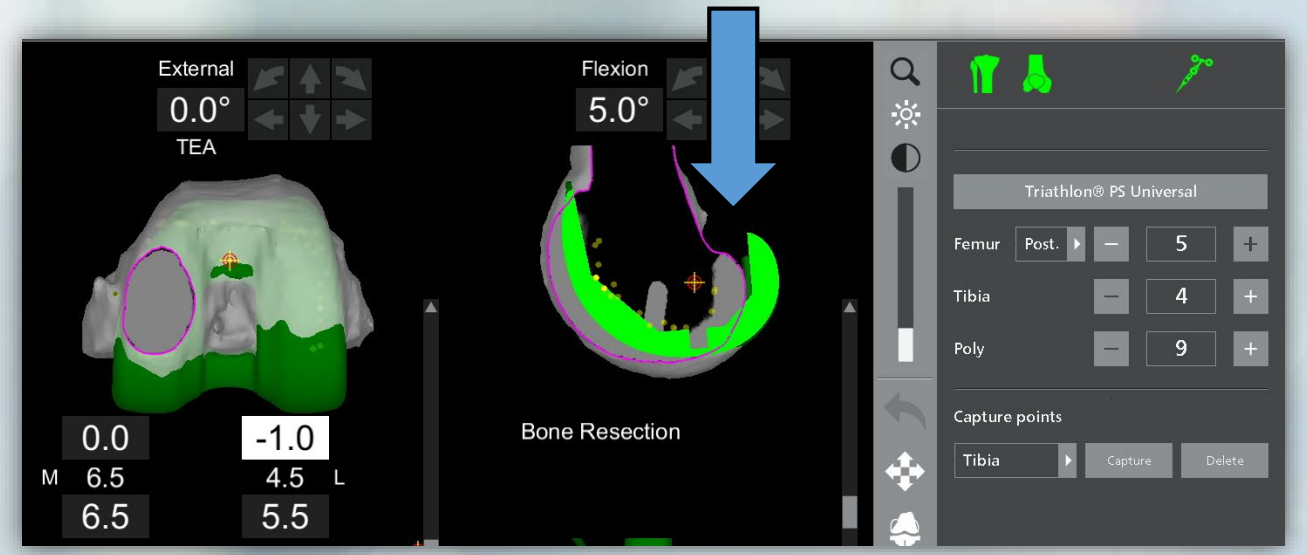

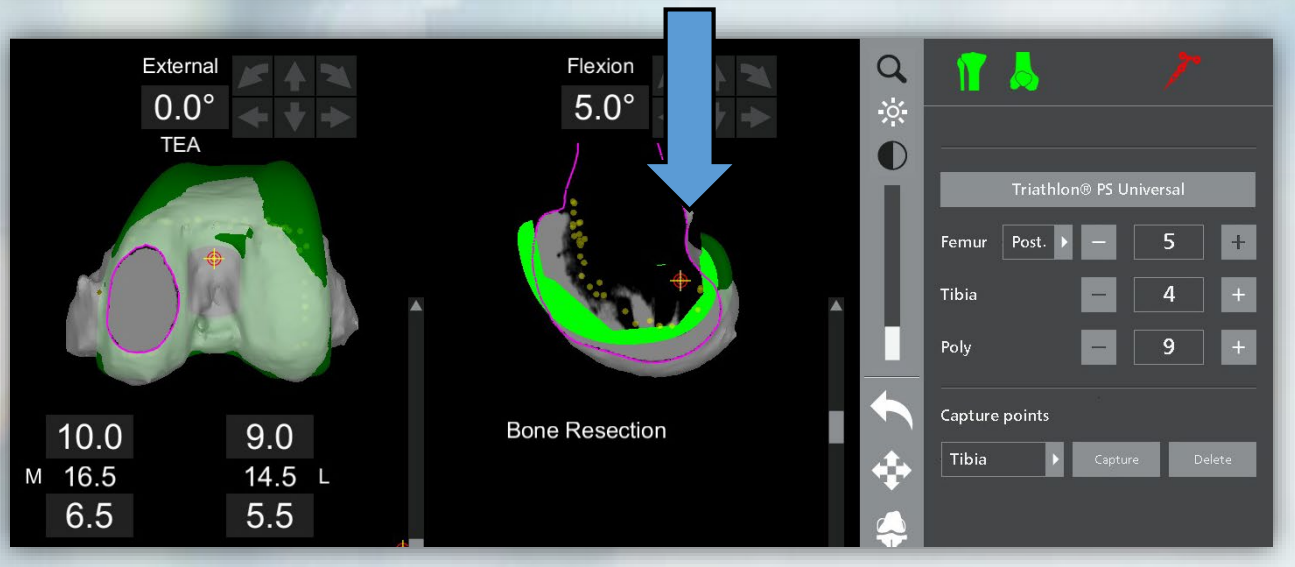

Missing Posterior Bone

Translate Femur Anterior 10 mm

Perform Posterior Condyle Cut

Translate Posterior 10 mm to original position

Cone & Stem Prep

Intramedullary Ream to stem size

Prepare for cone

Trial with augments

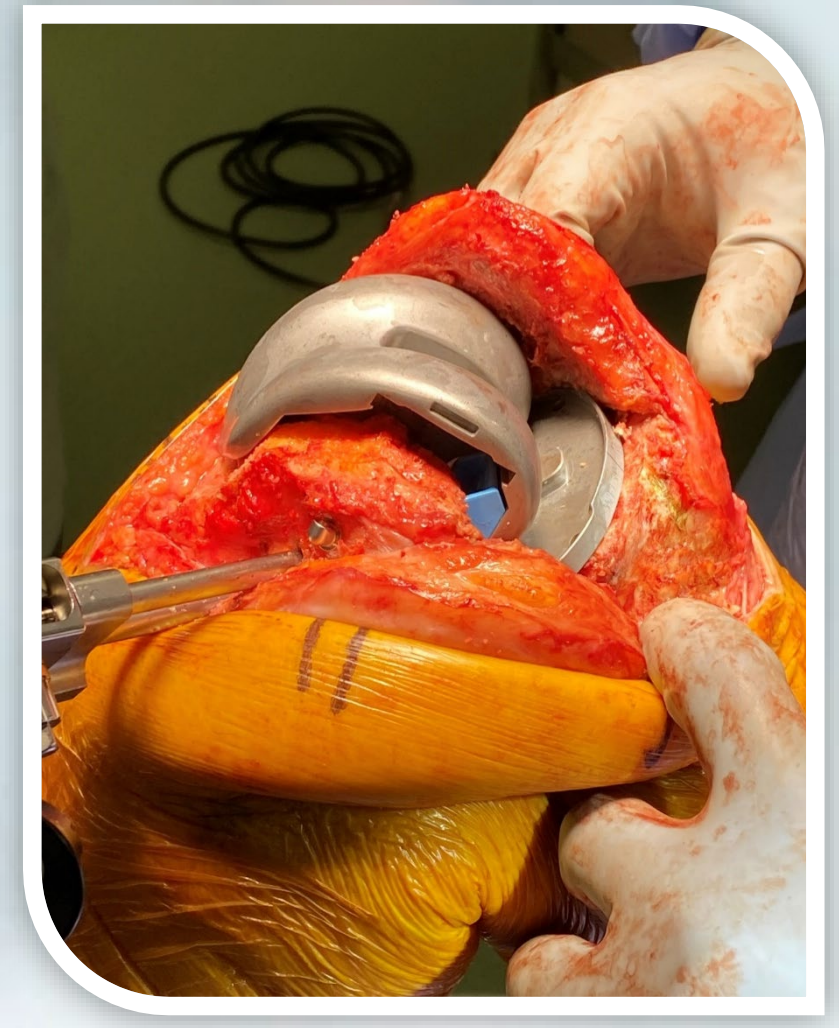

Faizan et al: JOA 2017
Jacquet et al: JOA 2021

Final Assessment

5 Femur (10 mm posterior augments)

5 Tibia with size C metaphyseal cone

19 mm TS poly

(Balanced 26 mm gaps)

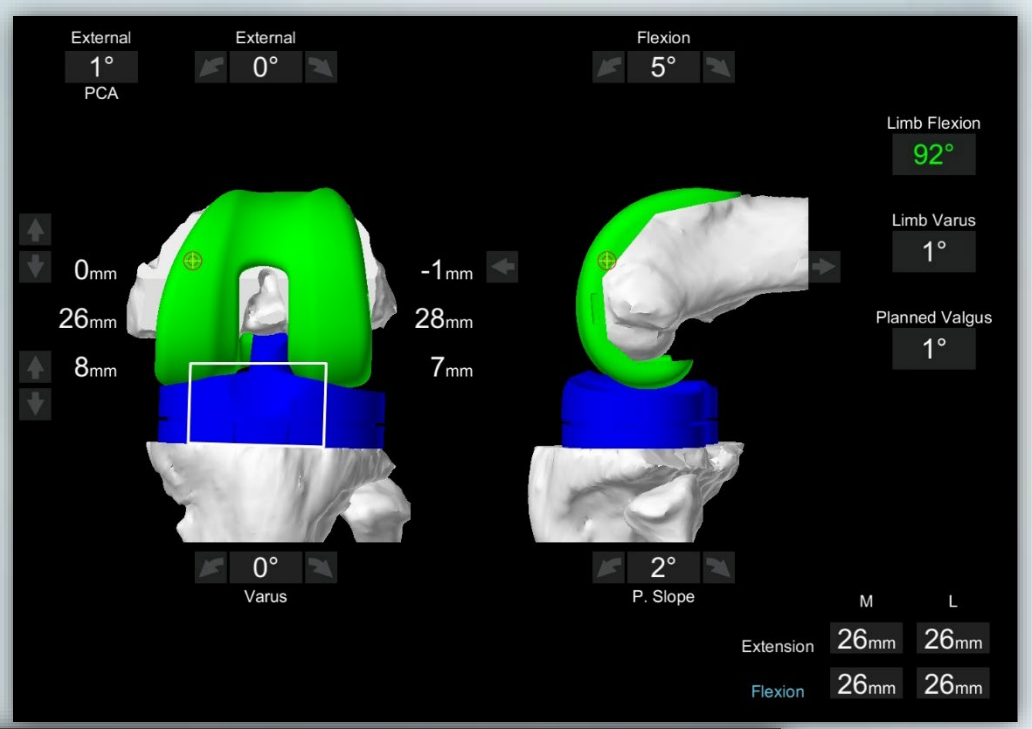

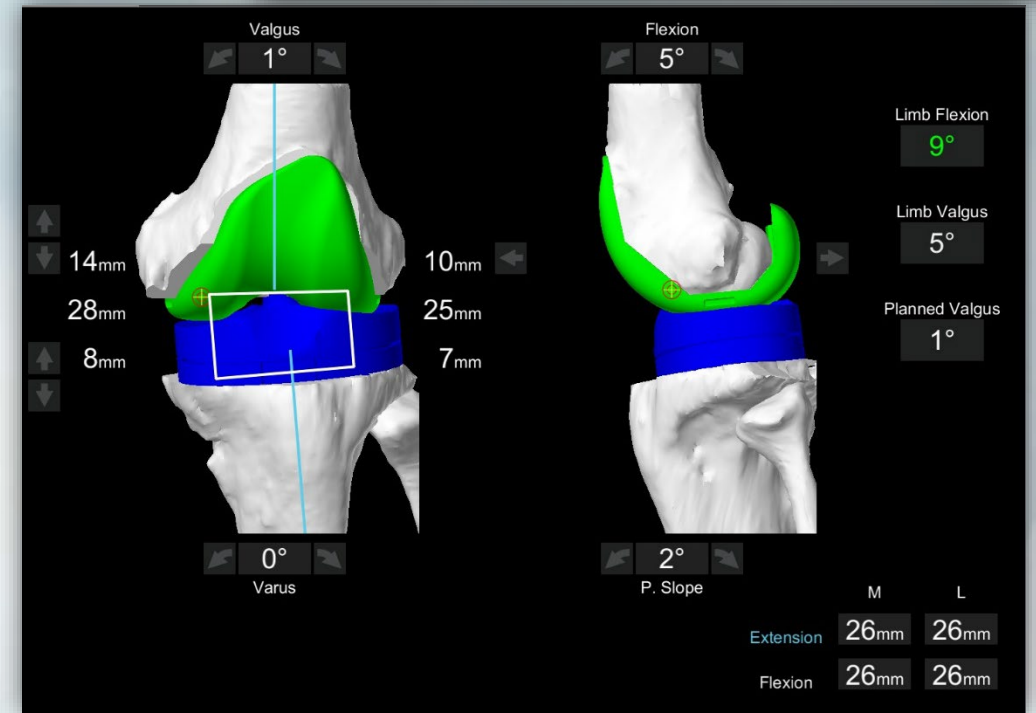

Final Motion Check

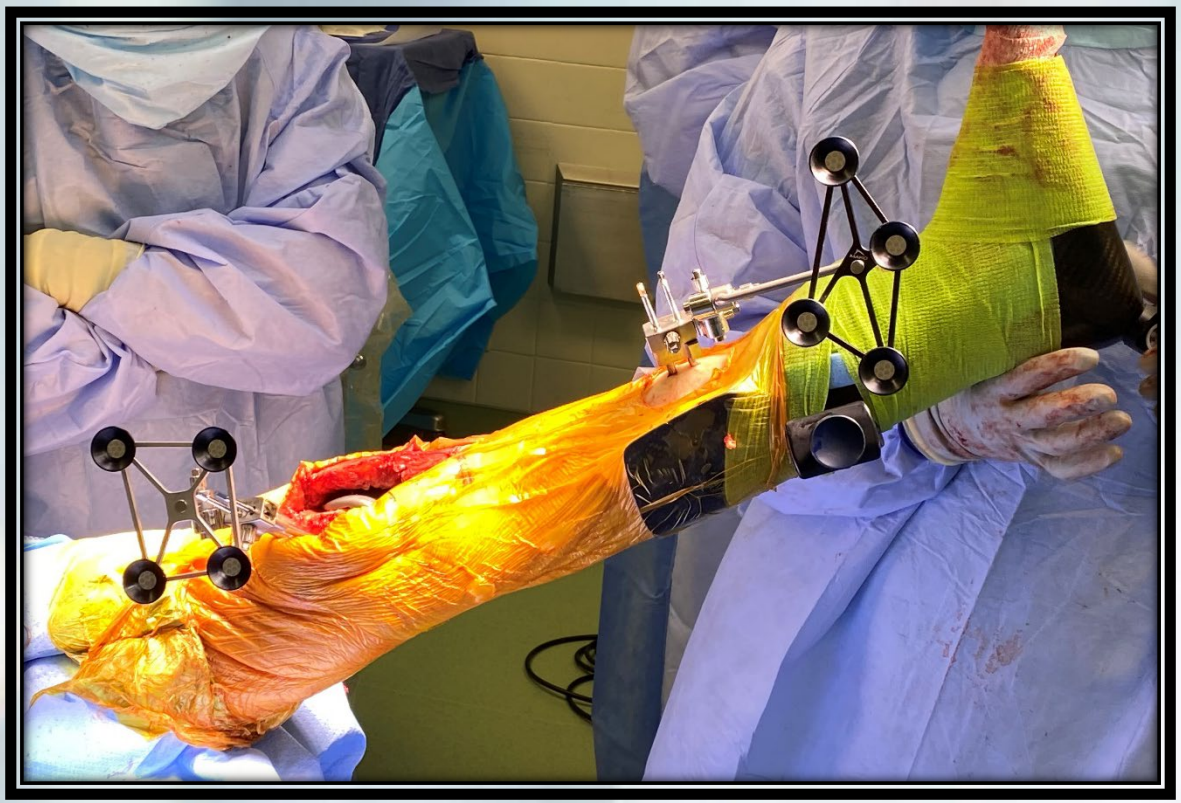

5-125 Degrees

Post-op

Overall Alignment

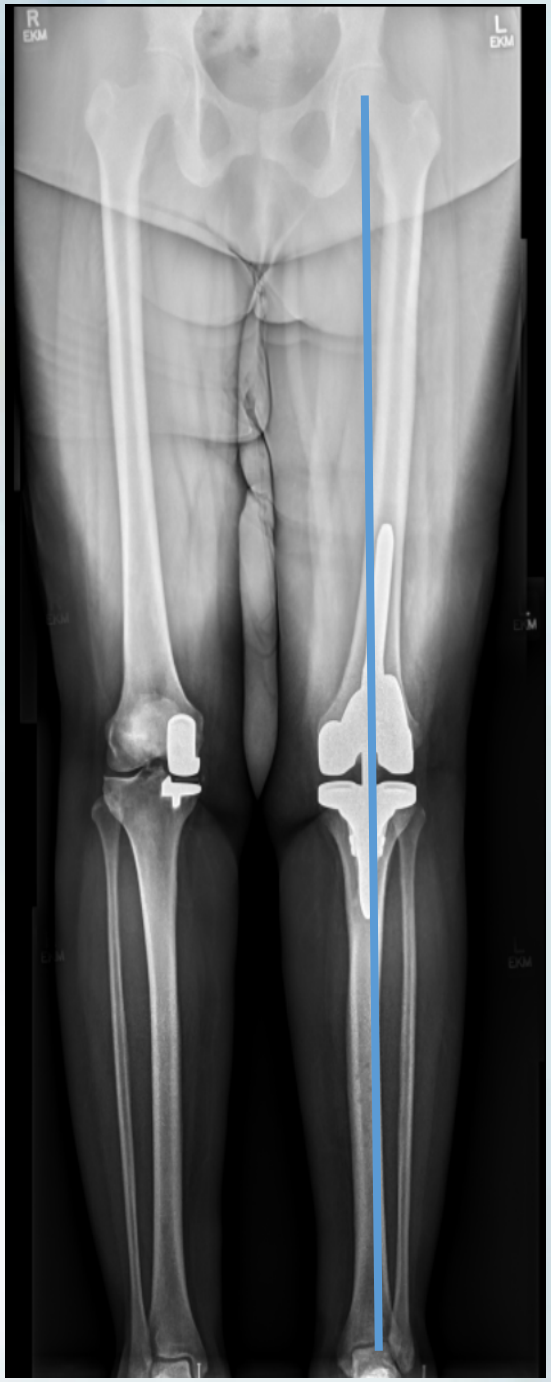

Pre-operative CT scan using Makoplasty protocol

Mako Product Specialist facilitates image segmentation/upload to Mako

↓

Array placement

Femoral pin in medial condyle; tibial pin in distal shin

Tibial pin ≥ 160mm from joint line recommended

↓

Intraoperative registration of bony landmarks

Poly removed prior to registration

May need registration on bone + implant due to artifact on pre-op CT

↓

Removal of femoral, tibial implants

↓

Assessment of dynamic stability at 0, 90°

Fine-tune component size, position based on flexion/extension gaps

↓

Review plan for implants

Position accordingly to balance flexion/extension gaps

Prepare for augmentation if necessary

↓

Perform bony cuts

Distal femur → posterior chamfer → change saw blades → proximal tibia → anterior femur → posterior femur → anterior chamfer

↓

Trial components

Stem +/- metaphyseal cones if necessary

↓

Cement final components with 2 cement batches

Cement tibia first, then femur with new batch

Summary

- Currently **OFF-LABEL**
- Unique option for **Select Patients**
- More Research needed…

MARSHALL

Marshall Orthopaedics