WHAT'S NEW IN TAA

Karim Boukhemis, MD
F&A Subspecialty
Wound Center Director
SMMC Chief of Orthopedics

69 YR MALE

- Initially injured in ’77
- ORIF at that time
- Finally failed conservative care
- Workers comp
- Injections initially offered some relief
- Failed bracing
- What next?

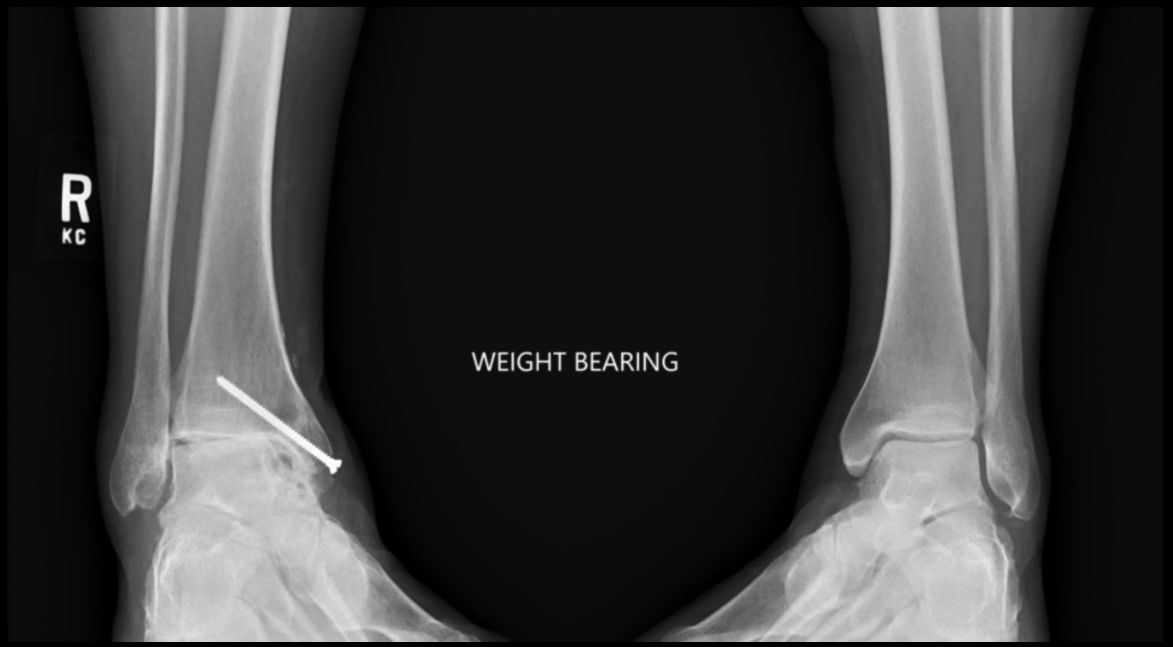
R
KC
WEIGHT BEARING


R
KC


BEARING

SOOO…..WE DID THIS


RT ANKLE
247503
BOUKHEMIS
3-CR-22-0056646
8:44:29 AM
32
26
64 kVp
1.78 mA
4
OEC


RT ANKLE
247503
BOUKHEMIS
31
24
61 kVp
1.54 mA
2

BUT WAIT….HOW DID WE GET HERE

- First we start with obtaining full length CT scan
  - This allows for extensive preop planning…

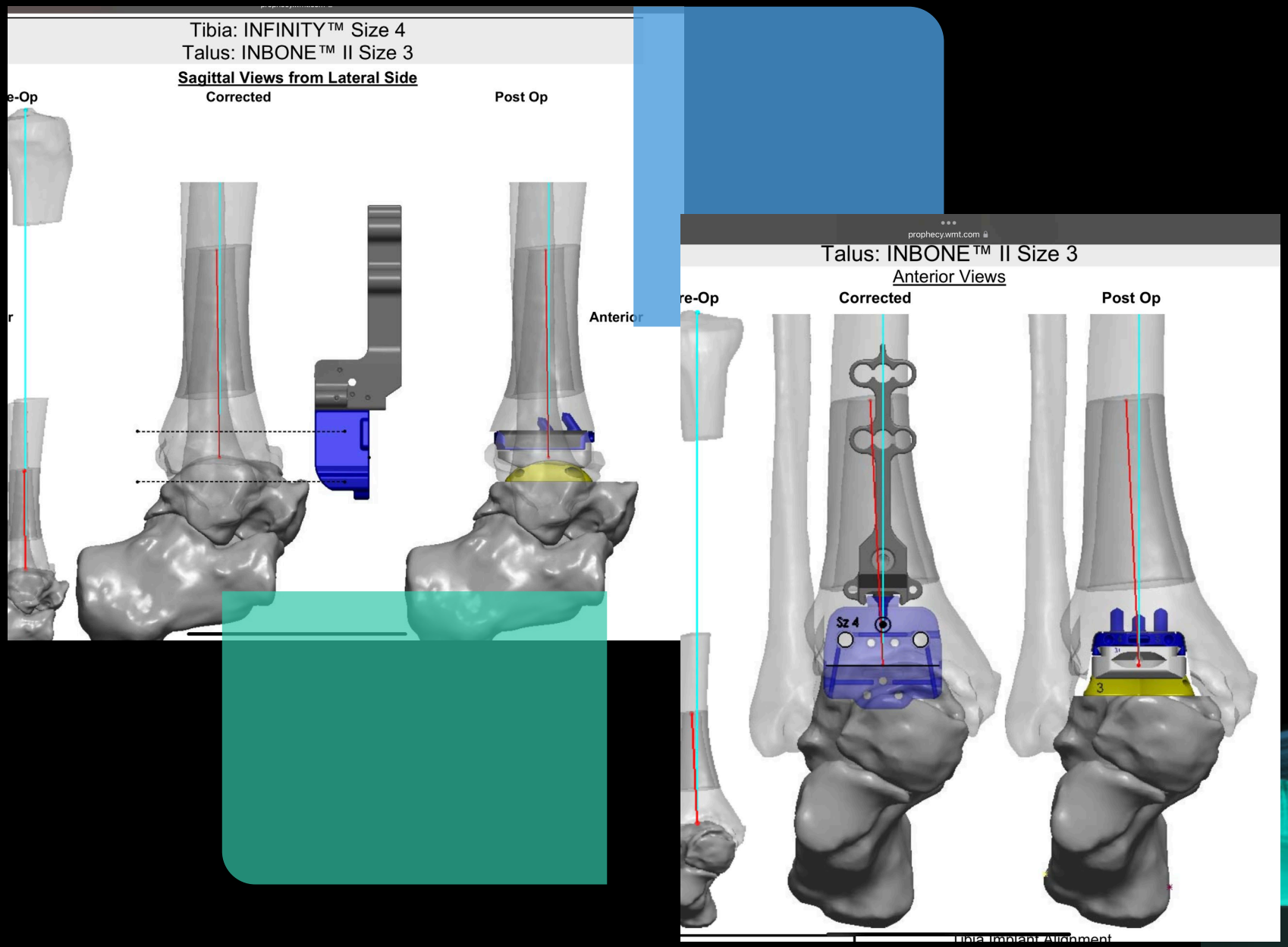

INITIAL REPORT

GIVES 3D VIEW OF DEFORMITY

Posterior

AP Direction: Gutter bisection

- Tibia gutter angle: 7.3°.
- A-P Tibia implant placement: Anterior edge. Posterior uncovered tibia resection: 1.7 mm.

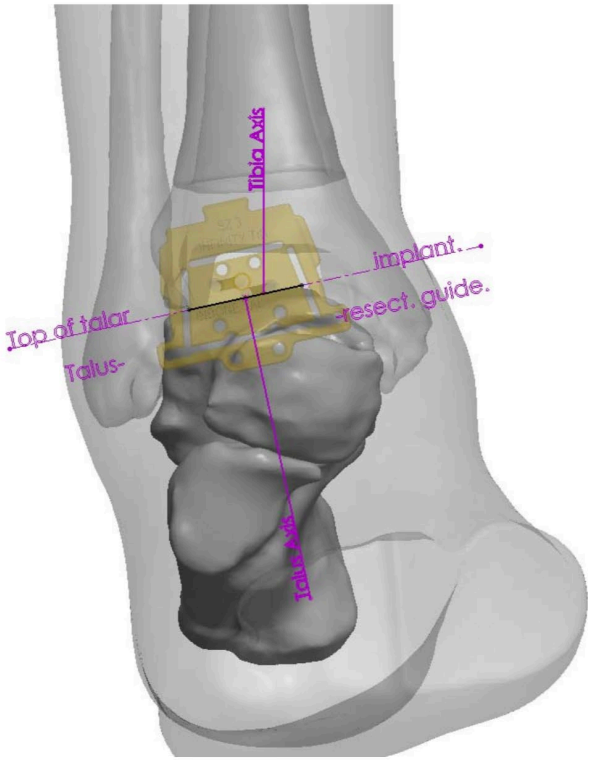

Talus resection guide relative to the talar bone and the planned tibia alignment axis. The resections will result in a correction of 12.3° from varus. Ligament balancing may be necessary to achieve balance

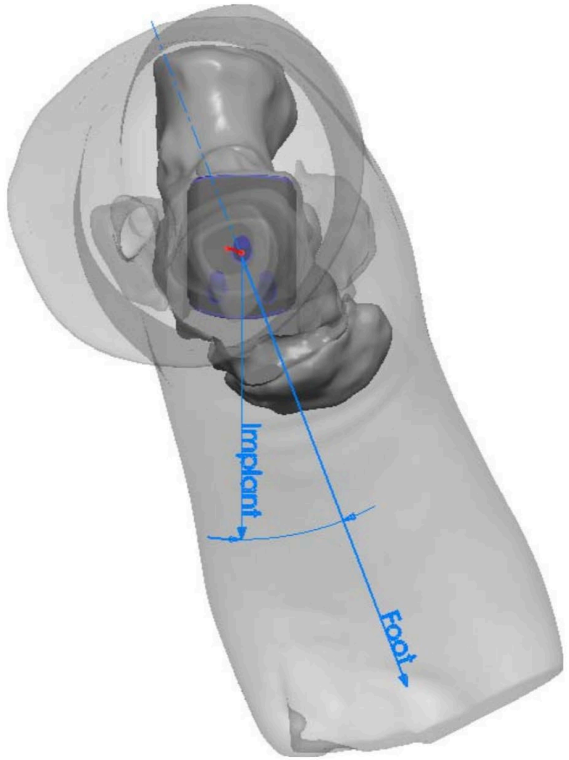

The tibia internal/external orientation is 21.1° external to the approximate foot orientation.

prophecy.wmt.com

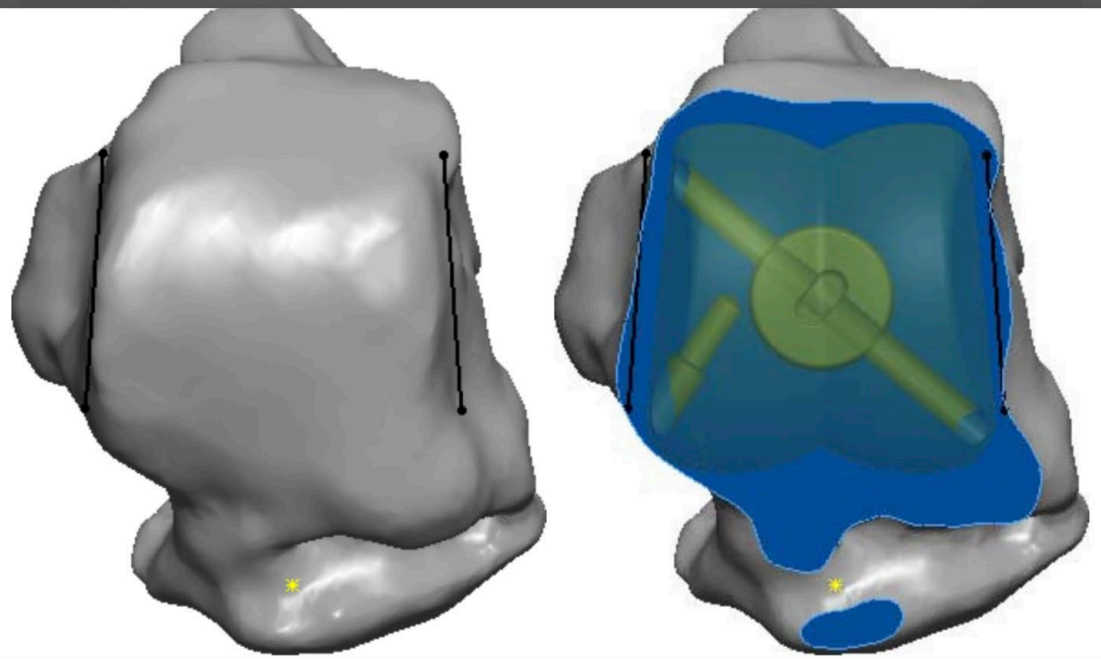

Lateral Medial Anterior Posterior

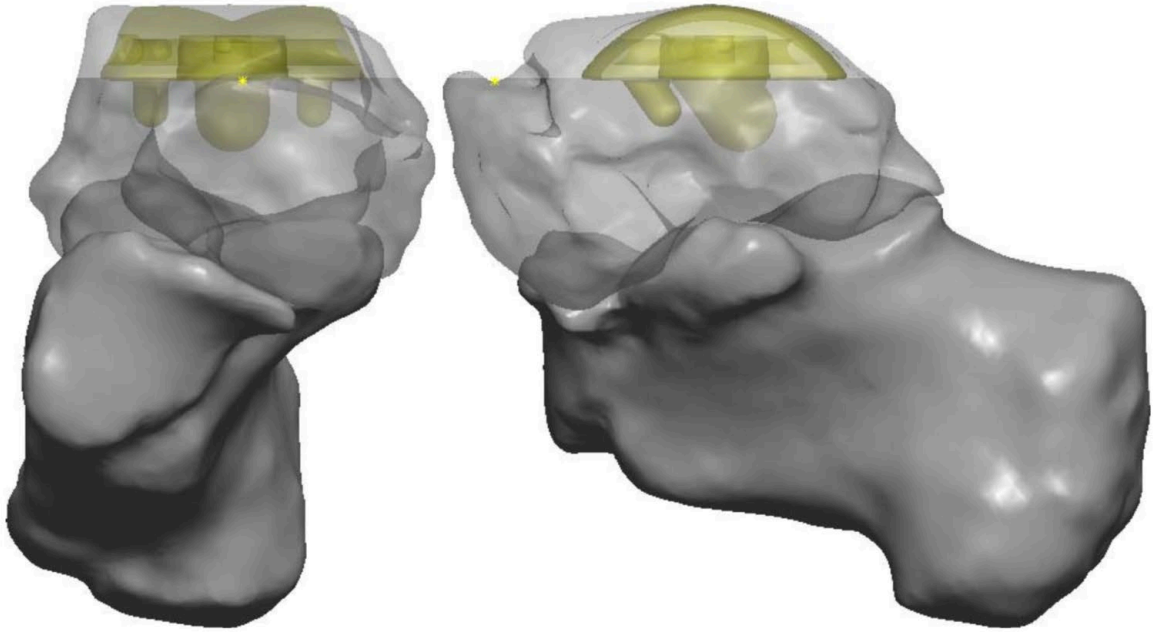

Anterior view Medial View

ACCURATE REPRESENTATION OF HWR PLACEMENT

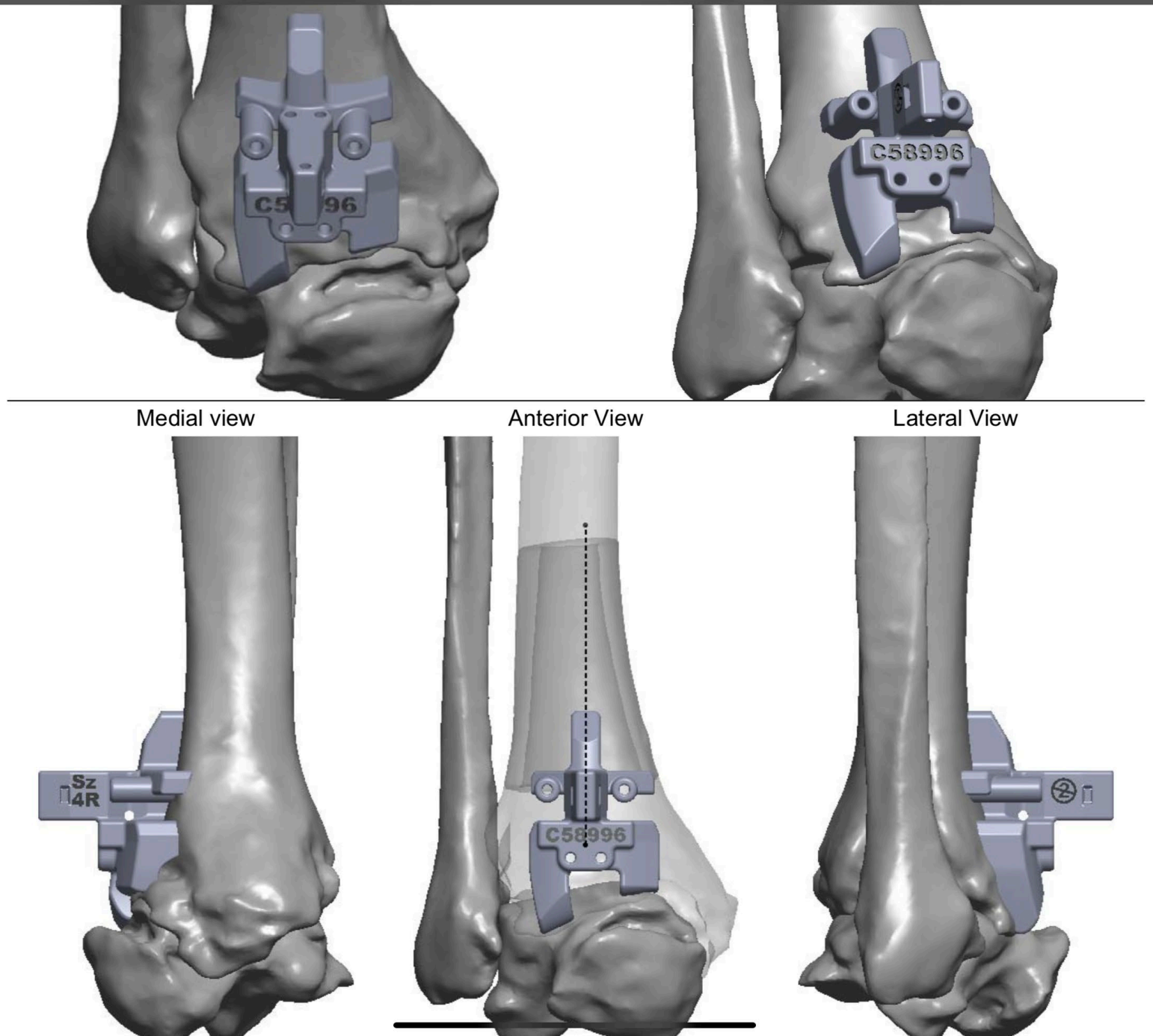

TIBIAL CUTTING JIG PLACEMENT

CORRECTION OF DEFORMITY REPRESENTED

Pre-op medial-lateral talar height difference: 5.7 mm

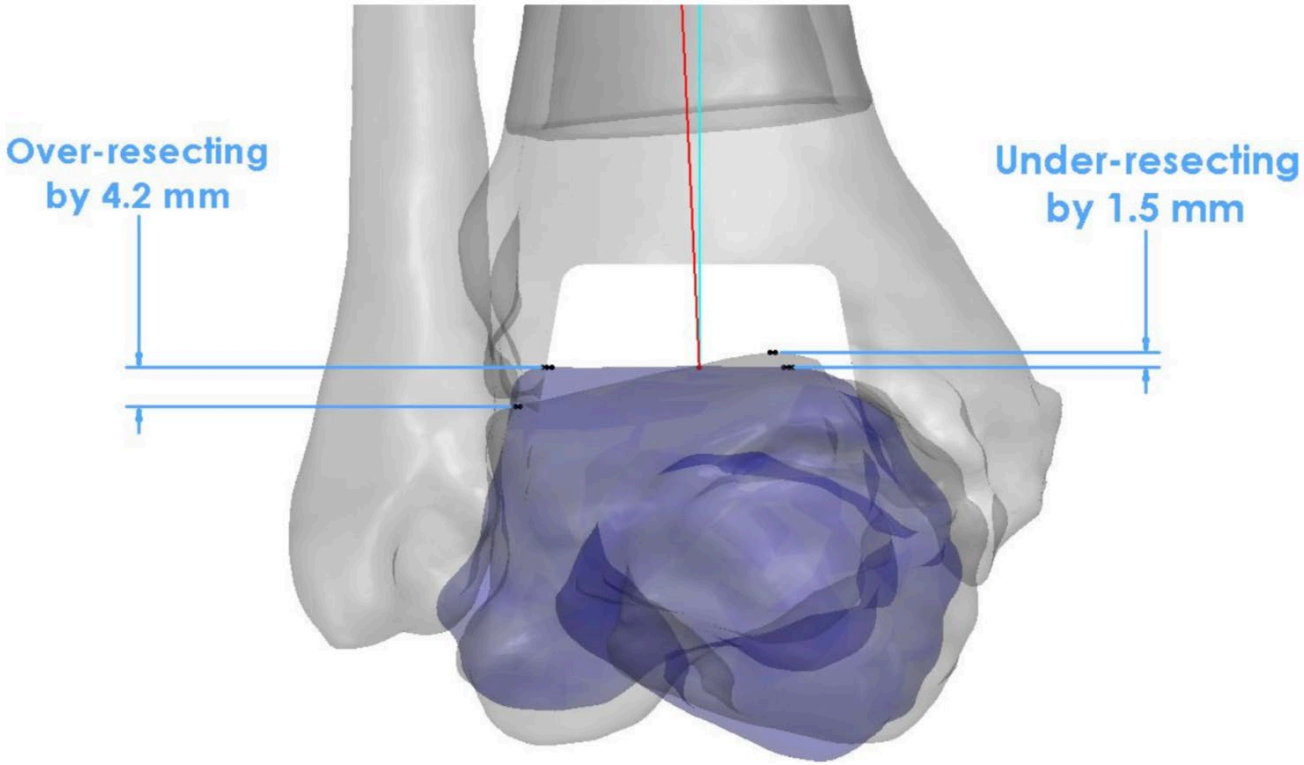

The swing of the talus & overall resection height (relative to standard implant height). The "corrected" talus is highlighted.

Talus resecti
bone and t
axis. The
correcti

The tibia re
as shown by
to restore sc
distal transl
resecting les
of the impla
likelihood
polyethylene

Given the cu
and the th
expected th
will be forc
resecting"
opposite sid
the amoun
value. Lig
necessary to

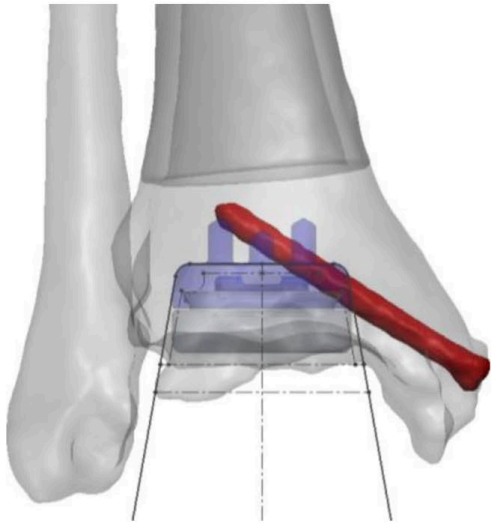

Anterior view

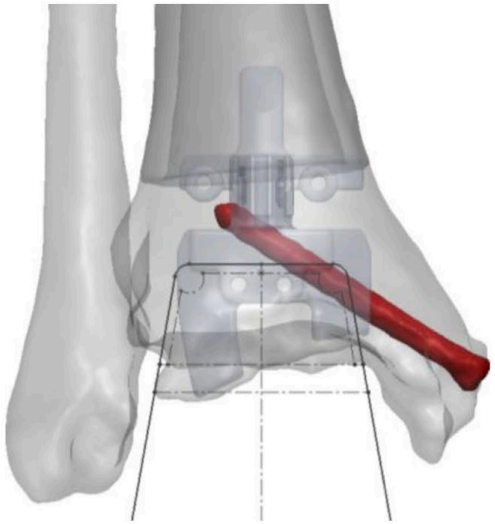

Anterior view – alignment guide

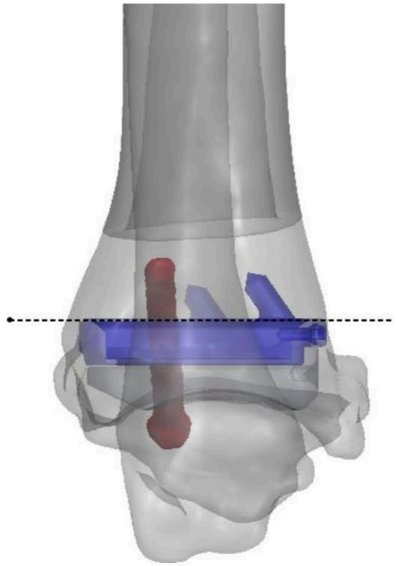

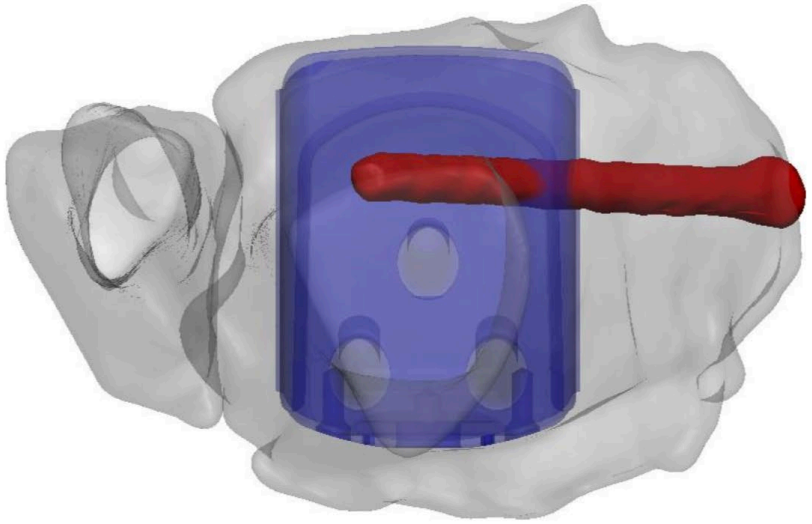

SHOWING PREDICTIVE IMPLANT PLACEMENT

DEFECTS HIGHLIGHTED

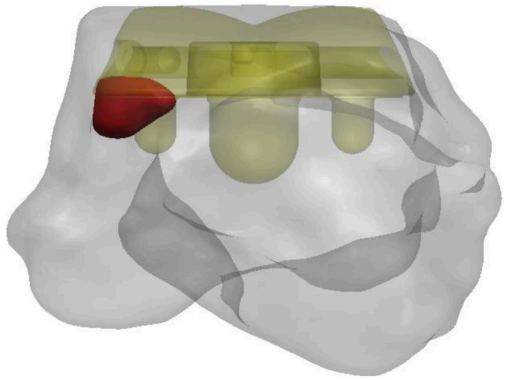

Anterior view of talus with implant.

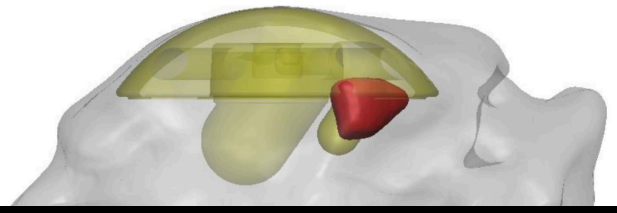

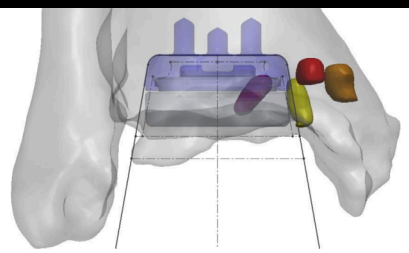

Anterior view of tibia and fibula.

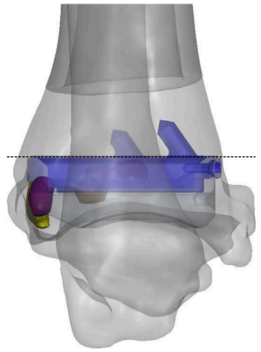

Lateral view of tibia and fibula.

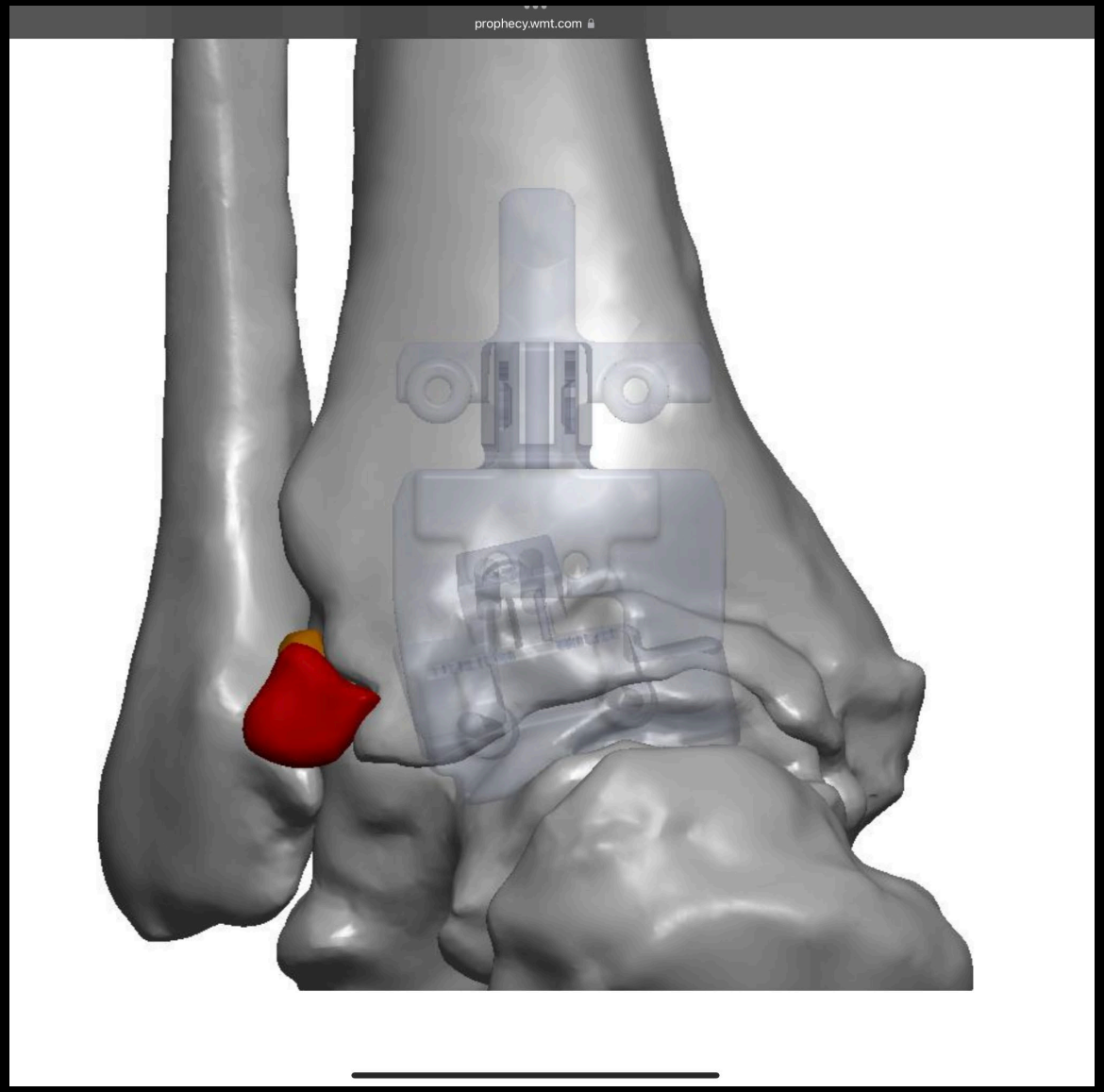

ANY POTENTIAL LOOSE BODIES TO BE REMOVED

FINALLY WITH GOOD PREPARATION....

MODIFICATION

- Ability to add more resection to avoid defects
- Allows adjustment of implant position
- Correct rotation
- Can use chamfer infinity talus, inbone talus, inbone tibia, or infinity talus
- Adjust implant based on CT scan
  - Invision talus/tibia

INIFINITY TALUS/TIBIA

- +/- to both options

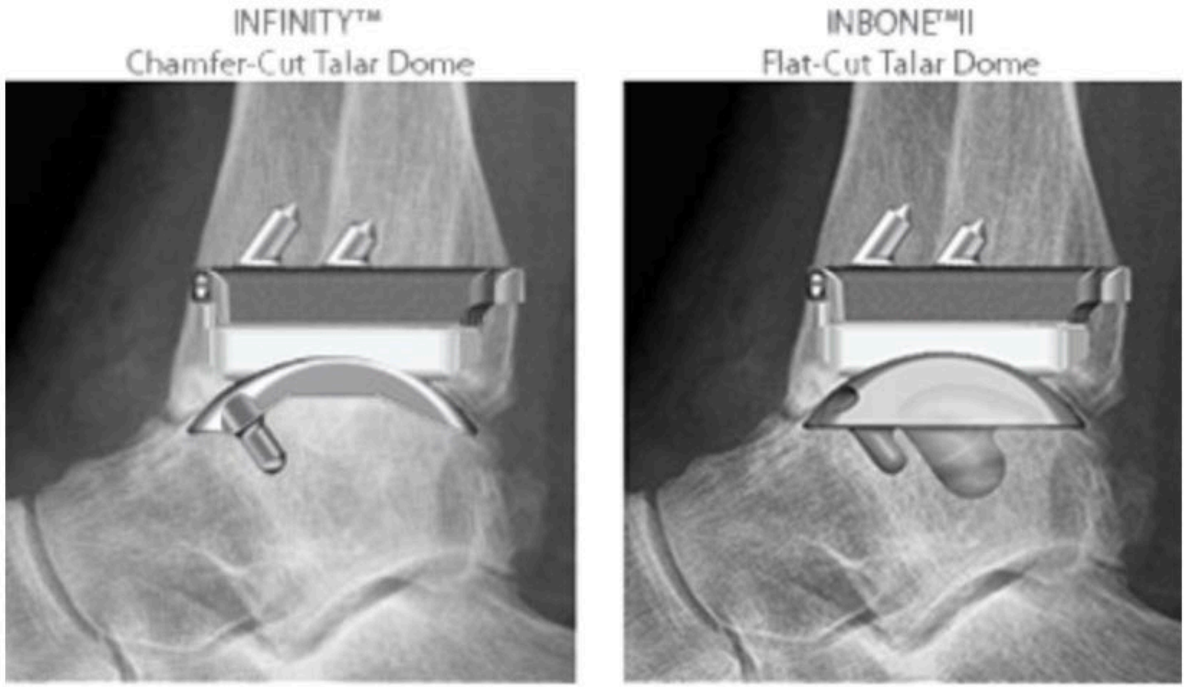

INCREASES STABILITY/FIXATION

- Typically recommended for older patients
- Can require drilling through subtalar joint

INBONE



FIRST REVISION SYSTEM….INVISION

- Allows better stability in collapsed talus
- Can help restore joint line
- Only available revision system on market at this time
- Works with prophecy

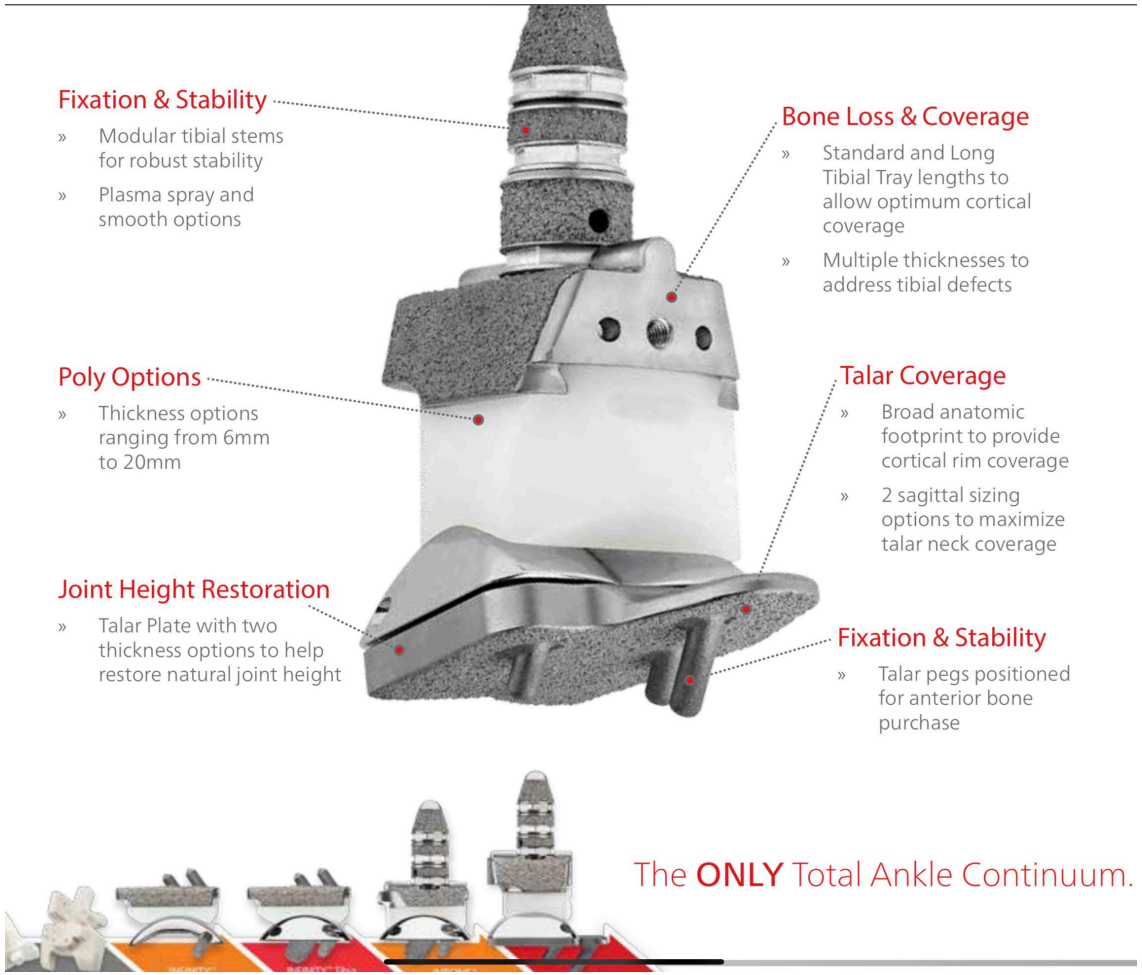

Clinical Application

Pre-op

Post-op

X-ray images courtesy of Steven Haddad, MD.



THANK YOU!