Current Concepts Review

# Diagnosis of Periprosthetic Infection

## Recent Developments

Amy S. Wasterlain, MD, Karan Goswami, MD, S. Ali Ghasemi, MD, and Javad Parvizi, MD, FRCS

*Investigation performed at the Rothman Orthopaedic Institute at Thomas Jefferson University, Philadelphia, Pennsylvania*

- There is no absolute test for the preoperative diagnosis of periprosthetic joint infection (PJI); thus, clinical practice relies on a combination of supportive tests and criteria.
- Novel serum and synovial tests have improved our ability to diagnose PJI. The 2018 evidence-based algorithm for PJI diagnosis provides weighted scores for serum markers, as well as synovial markers, to facilitate diagnosis when major criteria such as positive cultures or a sinus tract are not present.
- Culture-independent technologies such as next-generation sequencing can facilitate pathogen identification, particularly in the setting of culture-negative PJI.
- Despite recent developments, PJI diagnosis remains challenging and warrants further innovation.

Historically, the 2011 Musculoskeletal Infection Society (MSIS) criteria have been the standard for defining periprosthetic joint infection (PJI) after total joint arthroplasty (TJA)[1,2]. These criteria were developed by a workgroup of experts and represent the group's consensus on a "gold standard" definition of PJI based on the literature (Table I). According to the 2011 MSIS criteria, PJI definitely exists if 1 major or 4 minor criteria are met (Table II). PJI may still be present even if <4 minor criteria are present. Although the MSIS definition has been crucial in providing a standard for diagnosing and treating PJI, it has limitations. The criteria represent a consensus rather than an evidence-based algorithm. Three of the minor criteria rely on intraoperative findings, and 4 minor criteria must be met to confirm PJI. In addition, PJI cannot be diagnosed on the basis of the minor criteria preoperatively. The criteria may miss PJI caused by slow-growing organisms or culture-negative infections, and they do not include recently developed diagnostic tests.

### New Definition of PJI

Therefore, in 2018, the definition for PJI was updated to reflect new diagnostic tests and recently accrued evidence[3]. The 2018 definition was developed across 3 institutions by comparing 684 patients with proven PJI undergoing revision for infection and 820 patients with aseptic failure undergoing revision for a reason other than infection. Variables investigated were serum C-reactive protein (CRP), D-dimer, erythrocyte sedimentation rate (ESR), synovial white blood-cell (WBC) count, polymorphonuclear (PMN) percentage, leukocyte esterase (LE), alpha-defensin, synovial CRP, intraoperative frozen section, presence of purulence, and pathogen isolation by culture. Regression analyses were used to generate relative weights for each test, as not all tests have the same accuracy, and the new PJI definition (Table III) was then validated against external cohorts. The 2018 definition utilizes a stepwise approach for diagnosis (Table III). If either of the major criteria is present, the patient is infected. If no major criterion is present, the minor criteria are scored. A different score is assigned to each test, on the basis of pretest probability, and a score of ≥6 indicates infection. A score of ≤1 indicates the absence of infection. For patients with a score between 2 and 5 (a possible infection), additional tests and intraoperative findings should be incorporated. By using a stepwise approach, the new criteria take into account the relative weights and pretest probability of multiple tests.

**Disclosure:** The authors indicated that no external funding was received for any aspect of this work. On the **Disclosure of Potential Conflicts of Interest** forms, *which are provided with the online version of the article*, one or more of the authors checked "yes" to indicate that the author had a relevant financial relationship in the biomedical arena outside the submitted work and "yes" to indicate that the author had a patent and/or copyright, planned, pending, or issued, broadly relevant to this work (http://links.lww.com/JBJS/F908).

**TABLE I The Evolving Definition of PJI***

| | Acute PJI of <90 Days | Chronic PJI of >90 Days | Score | Definition |
|---|---|---|---|---|
| MSIS 2011 – Definition of PJI adapted from the Workgroup Convened by the MSIS[2]† | | | | |
| PJI is present if 1 of the major criteria or 4 of the 6 minor criteria exist: | | | | |
| Major criteria | | | | |
| 1. There is a sinus tract communicating with the prosthesis; or | | | | |
| 2. A pathogen is isolated by culture from 2 or more separate tissue or fluid samples obtained from the affected prosthetic joint; or | | | | |
| Minor criteria | | | | |
| 1. Elevated serum ESR and serum CRP concentration | | | | |
| 2. Elevated SF WBC count | | | | |
| 3. Elevated SF PMN% | | | | |
| 4. Presence of purulence in the affected joint | | | | |
| 5. Isolation of a microorganism in 1 culture of periprosthetic tissue or fluid, or | | | | |
| 6. Greater than 5 neutrophils per HPF in 5 HPFs observed from histologic analysis of periprosthetic tissue at ×400 magnification | | | | |
| IDSA 2013 – Definition modified from Osmon et al.[97]‡ | | | | |
| 1. The presence of a sinus tract that communicates with the prosthesis | | | | |
| 2. The presence of acute inflammation as seen on histopathologic examination of periprosthetic tissue at the time of surgical debridement or prosthesis removal | | | | |
| 3. The presence of purulence without another known etiology surrounding the prosthesis | | | | |
| 4. Two or more intraoperative cultures or combination of preoperative aspiration and intraoperative cultures that yield the same organism. . . . Growth of a virulent microorganism (e.g., *Staphylococcus aureus*) in a single specimen of a tissue biopsy or synovial fluid may also represent PJI | | | | |
| 5. The presence of PJI is possible even if the above criteria are not met; the clinician should use his or her clinical judgment to determine if this is the case after reviewing all the available preoperative and intraoperative information | | | | |
| ICM 2013 – Definition adapted from Parvizi and Gehrke[98]§ | | | | |
| PJI is present if 1 of 2 major criteria or 3 of 5 minor criteria exist: | | | | |
| Major criteria | | | | |
| 1. Two positive periprosthetic cultures with phenotypically identical organisms; or | | | | |
| 2. A sinus tract communicating with the joint; or | | | | |

*continued*

**TABLE I (*continued*)**

| | Acute PJI of <90 Days | Chronic PJI of >90 Days | Score | Definition |
|---|---|---|---|---|
| Having 3 of the following minor criteria | | | | |
| 1. Elevated ESR and CRP | ESR: no threshold; or CRP of >100 mg/L | ESR of >30 mm/h or CRP of >10 mg/L | | |
| 2. Elevated SF WBC count or ++ change on LE test strip | ≥10,000 cells/μL; or + or ++ | ≥3,000 cells/μL; or + or ++ | | |
| 3. Elevated SF PMN% | ≥90% | ≥80% | | |
| 4. Positive histologic analysis of periprosthetic tissue | >5 neutrophils/HPF in 5 HPFs (×400) | >5 neutrophils/HPF in 5 HPFs (×400) | | |
| 5. A single positive culture | | | | |
| The 2018 definition of PJI—an evidence-based and validated version modified from Parvizi et al.[3]# | | | | |
| Major criteria (at least one of the following) | | | | Infected |
| Two positive cultures of the same organism | | | | |
| Sinus tract with evidence of communication to the joint or visualization of the prosthesis | | | | |
| Minor criteria | | | | |
| Preoperative diagnosis | | | | ≥6 infected; 2-5 possibly infected**; 0-1 not infected |
| Serum | | | | |
| Elevated CRP or D-dimer | | | 2 | |
| Elevated ESR | | | 1 | |
| Synovial fluid | | | | |
| Elevated synovial WBC or LE (++) | | | 3 | |
| Positive alpha-defensin | | | 3 | |
| Elevated synovial PMN% | | | 2 | |
| Elevated synovial CRP | | | 1 | |
| Intraoperative diagnosis** | | | | ≥6 infected; 4-5 inconclusive††; ≤3 not infected |
| Preoperative score | | | – | |
| Positive histological findings | | | 3 | |
| Positive purulence | | | 3 | |
| Positive single culture | | | 2 | |

*MSIS = Musculoskeletal Infection Society, PJI = periprosthetic joint infection, ESR = erythrocyte sedimentation rate, CRP = C-reactive protein, SF WBC = synovial fluid white blood-cell count, SF PMN% = synovial fluid polymorphonuclear percentage, HPF = high-power field, IDSA = Infectious Diseases Society of America, ICM = International Consensus Meeting, and LE = leukocyte esterase. †The MSIS 2011 table is reproduced, with modification, from: Workgroup Convened by the Musculoskeletal Infection Society, New definition for periprosthetic joint infection. J Arthroplasty. 2011;26(8):1136-8. Copyright 2011; with permission from Elsevier. ‡The IDSA 2013 table is reproduced, with modification, from: Osmon DR, Berbari EF, Berendt AR, Lew D, Zimmerli W, Steckelberg JM, Rao N, Hanssen A, Wilson WR, Infectious Diseases Society of America. Diagnosis and management of prosthetic joint infection: clinical practice guidelines by the Infectious Diseases Society of America. Clin Infect Dis. 2013;56(1):e1-e25, by permission of the Infectious Diseases Society of America. §The ICM 2013 table is reproduced, with modification, from: Parvizi J, Gehrke T; International Consensus Group on Periprosthetic Joint Infection. Definition of periprosthetic joint infection. J Arthroplasty. 2014 Jul;29(7):1331. Copyright 2014. Reproduced with permission. #The 2018 definition table is reproduced from: Parvizi J, Tan TL, Goswami K, Higuera C, Della Valle C, Chen AF, Shohat N. The 2018 definition of periprosthetic hip and knee infection: an evidence-based and validated criteria. J Arthroplasty. 2018 May;33(5): 1309-1314.e2. Copyright 2018, with permission from Elsevier. **For patients with inconclusive preoperative score or dry tap, operative criteria can also be used to fulfill the definition for PJI. ††Consider further molecular diagnostics such as next-generation sequencing.

**TABLE II 2011 Musculoskeletal Infection Society Criteria for the Diagnosis of PJI*†**

| |
|---|
| Major criteria |
| There is a sinus tract communicating with the prosthesis; or |
| A pathogen is isolated by culture from 2 or more separate tissue or fluid samples obtained from the affected prosthetic joint; or |
| Minor criteria |
| Elevated serum ESR and serum CRP concentration |
| Elevated synovial white blood cell count |
| Elevated synovial polymorphonuclear percentage |
| Presence of purulence in the affected joint |
| Isolation of a microorganism in 1 culture of periprosthetic tissue or fluid, or |
| Greater than 5 neutrophils per high-power field (HPF) in 5 separate HPFs observed from histologic analysis of periprosthetic tissue at ×400 magnification |

*Reproduced from: The Workgroup Convened by the Musculoskeletal Infection Society. New definition for periprosthetic joint infection. J Arthroplasty. 2011;26(8):1136-8. Copyright 2011; with permission from Elsevier. †According to these criteria, PJI definitely exists if 1 major criterion or 4 minor criteria are met.

The 2018 system has a 97.7% sensitivity and 99.5% specificity, compared with 86.9% sensitivity and 79.3% specificity of the 2011 MSIS criteria[3]. That said, major criteria were utilized as a gold standard for model development, and further external validation studies outside the institutions developing this definition are needed to determine generalizability.

## Serum and Synovial Markers for PJI

A number of serum and synovial markers have been explored to aid in PJI diagnosis. The reported accuracy of these tests has varied among studies on the basis of what was used as the gold standard to define PJI. The studies also utilized different thresholds for some tests, which had an impact on the results presented.

### *Serum Markers for Diagnosis of PJI*

#### D-Dimer

Early diagnosis of PJI is critical because there is a short window of opportunity to treat acute infection with debridement and implant retention before the development of biofilm. However, the diagnosis of PJI in the postoperative period can be a challenge because ESR and CRP remain elevated for 6 and 2 weeks, respectively[4]. This has prompted a search for a serum marker that may return to baseline levels early after arthroplasty.

D-dimers are fibrin degradation products that form when plasmin dissolves the fibrin clot. The presence of elevated serum D-dimer levels has been associated with numerous inflammatory conditions including venous thromboembolism, cancer, and infection[5,6]. Shahi et al. observed that D-dimer was significantly elevated in patients with PJI compared with those with aseptic failures (1,110 and 299 ng/mL, respectively; $p < 0.0001$), and that 850 ng/mL was the optimal serum D-dimer threshold value for PJI diagnosis[7]. D-dimer was more accurate in predicting the presence of infection than the combination of ESR and CRP.

Lee et al. measured serum ESR, CRP, and D-dimer in 65 TJA patients before and after surgery[4]. D-dimer levels peaked on postoperative day 1 and returned to baseline by postoperative day 2; D-dimers rose again at 2 weeks (Fig. 1). As the level of D-dimer rises and falls more rapidly than ESR and CRP in the acute postoperative period, it is possible that D-dimer may be a useful test in conjunction with ESR and CRP to diagnose

**TABLE III 2018 Evidence-Based Stepwise Algorithm for Diagnosis of PJI Adapted from Parvizi et al.***

| Criteria | Score (points) | Decision |
|---|---|---|
| Major criteria (at least 1 of the following) | | Infected |
| Two positive cultures of the same organism | | |
| Sinus tract with evidence of communication to the joint or visualization of the prosthesis | | |
| Minor criteria | | |
| Preoperative diagnosis | | ≥6 infected; 2-5 possibly infected†; 0-1 not infected |
| Serum | | |
| Elevated CRP or D-dimer | 2 | |
| Elevated ESR | 1 | |
| Synovial | | |
| Elevated synovial WBC count or LE | 3 | |
| Positive alpha-defensin | 3 | |
| Elevated synovial PMN (%) | 2 | |
| Elevated synovial CRP | 1 | |
| Intraoperative diagnosis† | | ≥6 infected; 4-5 inconclusive‡; ≤3 not infected |
| Preoperative score | – | |
| Positive histology | 3 | |
| Positive purulence | 3 | |
| Single positive culture | 2 | |

*Reproduced from: Parvizi J, Tan TL, Goswami K, Higuera C, Della Valle C, Chen AF, Shohat N. The 2018 definition of periprosthetic hip and knee infection: an evidence-based and validated criteria. J Arthoplasty. 2018;33(5):1309-1314.e2. Copyright 2018; with permission from Elsevier. †In the case of an inconclusive preoperative score or a dry tap, operative criteria can also be used to fulfill the definition for PJI. ‡Consider further molecular diagnostics such as next-generation sequencing if diagnosis remains inconclusive.

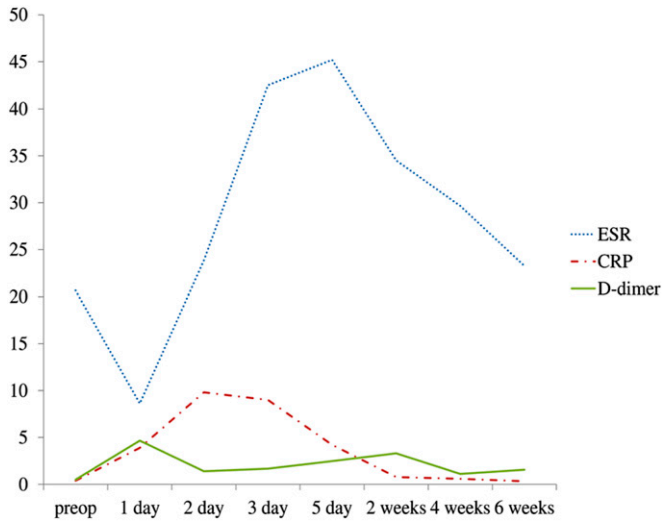


Fig. 1

Trend of serum D-dimer (ng/dL), ESR (mm/hr), and CRP (mg/dL) levels after TJA. (Adapted, under Creative Commons Attribution 4.0 International License, from: Lee YS, Lee Y-K, Han SB, Nam CH, Parvizi J, Koo K-H. Natural progress of D-dimer following total joint arthroplasty: a baseline for the diagnosis of the early postoperative infection. J Orthop Surg Res. 2018 Feb 13;13[1]:36.)

and monitor early acute PJI[4]. A low D-dimer level in the early postoperative period may be helpful in ruling out PJI.

A limitation of D-dimer is that it is nonspecific, and elevated D-dimer could indicate the presence of an inflammatory state unrelated to infection. Skepticism regarding D-dimer was raised by Li et al.[8], who reported a limited diagnostic value with an area under the curve (AUC) of 0.657. The latter report involved a Chinese patient population, with no patient being excluded, and a different threshold for PJI diagnosis was used. The report highlighted the potential issues that may exist with this serum test, and further studies are needed.

**Fibrinogen**

Fibrinogen is a soluble glycoprotein that is the precursor to fibrin in the clotting cascade, and it assists in activating and mediating the inflammatory cascade[9]. In a study of 84 patients undergoing revision total hip arthroplasty or total knee arthroplasty for septic or aseptic loosening, a serum fibrinogen value of 574 mg/dL had a sensitivity of 81% and a specificity of 25%[10]. This implies that a low fibrinogen level can help rule out PJI. This has been corroborated in a multicenter report that demonstrated an AUC of 0.852, sensitivity of 76%, and specificity of 86%[8]. However, like D-dimer, fibrinogen is nonspecific for PJI.

**Interleukin (IL)-6**

IL-6 is produced by monocytes and macrophages as part of an activated immune response, and it induces the production of acute phase reactants such as CRP[11]. The serum IL-6 level is approximately 1 pg/mL at baseline and can increase to 430 pg/mL for 3 days after TJA[11]. The peak occurs 2 days after TJA, after which it rapidly returns to normal[12]. Serum IL-6 is significantly elevated in patients with PJI compared with patients with aseptic loosening[13]. At a cutoff value of 2.6 pg/mL, IL-6 was 58% specific and 80% sensitive for PJI detection; when the cutoff was raised to 6.6 pg/mL, specificity increased to 88%, but sensitivity decreased to 48%.

**Procalcitonin**

Procalcitonin is produced by thyroid parafollicular and lung neuroendocrine cells and has a half-life of 22 to 29 hours. Procalcitonin levels rise rapidly in response to bacterial, but not viral or fungal, infections. A meta-analysis demonstrated that procalcitonin outperformed serum CRP in correctly predicting patients with septic arthritis[14]. However, in a study that screened synovial markers for PJI, procalcitonin had low accuracy[15].

***Synovial Markers for Diagnosis of PJI***

Numerous synovial biomarkers have been analyzed for possible utility for PJI diagnosis. Those with sufficient data from pooled analyses are summarized in Table IV. The synovial markers with greatest diagnostic promise appear to be alpha-defensin, LE, IL-6, and IL-8.

**Alpha-Defensin**

Alpha-defensin is an antimicrobial peptide released by activated neutrophils, which then integrates into and destroys the bacterial cell membrane[15,16]. A cutoff for synovial alpha-defensin of 4.8 ug/mL was 100% specific and 100% sensitive for diagnosing PJI in 1 study[15]. A meta-analysis demonstrated that elevation of alpha-defensin beyond the threshold was 100% sensitive and 96% specific for PJI, with an AUC of 0.99[17]. Combining alpha-defensin with synovial CRP increased the specificity of the test to 100%[18].

Alpha-defensin performs well in challenging situations like culture-negative PJI, systemic inflammatory conditions, and concurrent antibiotic use[18,19]. Alpha-defensin also appears to be triggered by a wide array of pathogens, with no difference in the magnitude of the alpha-defensin level[20]. However, alpha-defensin has limitations, with low positive predictive value (PPV) and specificity in the setting of metallosis or adverse local tissue reactions (ALTR)[21,22]. On review of the available literature by the 2019 American Academy of Orthopaedic Surgeons Diagnosis and Prevention of Periprosthetic Joint Infections Clinical Practice Guideline, alpha-defensin testing was noted to be useful for ruling in PJI (positive likelihood ratio [LR] range = 4.36 to 32.33) and ruling out PJI (positive LR = 0.03 to 0.36)[23]. However, the test's rule-out ability as a screening tool for infection has been questioned because of the limited sensitivity reported elsewhere in the literature[24-26].

At the time of writing, there were 2 commercially available tests that measure alpha-defensin in combination with other biomarkers (synovial CRP and human neutrophil elastase): (1) a laboratory-based enzyme-linked immunosorbent assay (ELISA) test, which produces a numerical value within a

**TABLE IV Sensitivity and Specificity of Synovial Biomarkers***

| Test | Sensitivity† | Specificity† | Log DOR† | AUC‡ |
|---|---|---|---|---|
| Leukocyte count | 0.89 (0.86-0.91) | 0.86 (0.80-0.90) | 4.17 (3.69-4.65) | 0.91 |
| PMN% | 0.89 (0.82-0.93) | 0.86 (0.77-0.92) | 4.05 (3.02-5.08) | 0.93 |
| CRP | 0.85 (0.78-0.90) | 0.88 (0.78-0.94) | 4.15 (2.89-5.41) | 0.90 |
| α-defensin | 0.97 (0.93-0.99) | 0.96 (0.94-0.98) | 6.70 (5.65-7.75) | 0.99 |
| LE | 0.77 (0.63-0.87) | 0.95 (0.86-0.98) | 4.57 (3.46-5.67) | 0.92 |
| IL-6 | 0.81 (0.70-0.89) | 0.94 (0.88-0.97) | 4.38 (2.86-5.89) | 0.95 |
| IL-8 | 0.87 (0.67-0.96) | 0.94 (0.88-0.97) | 4.92 (2.84-7.00) | 0.96 |
| Culture | 0.62 (0.50-0.74) | 0.94 (0.91-0.96) | 3.27 (2.64-3.90) | 0.94 |

*Reproduced from: Lee YS, Koo KH, Kim HJ, Tian S, Kim TY, Maltenfort MG, Chen AF. Synovial fluid biomarkers for the diagnosis of periprosthetic joint infection: a systematic review and meta-analysis. J Bone Joint Surg Am. 2017 Dec 20;99(24):2077-84. †The 95% confidence interval is given in parentheses. DOR = diagnostic odds ratio. ‡AUC = area under the curve.

few days, and (2) a point-of-care lateral flow test (Synovasure; Zimmer Biomet), which produces a binary positive or negative result within minutes. The majority of the reported results regarding the utility of alpha-defensin have assessed the laboratory-based ELISA assay and not the point-of-care test. A meta-analysis of 42 articles suggested that the ELISA assay performs better than the lateral flow test[27]. Specifically, the lateral flow test has lower overall accuracy (AUC of 0.75 versus 0.98 for the ELISA assay), but it remains relatively specific (90% versus 96%)[28]. Therefore, the lateral flow test may still be a useful rapid test to "rule in" infection. The lateral flow test was recently approved in the U.S., and further work assessing the accuracy is needed.

**Calprotectin**

Like many of the other synovial biomarkers, calprotectin is an antimicrobial molecule that is released by activated neutrophils and is therefore a marker of infection. With a cutoff value of 50 mg/L, synovial calprotectin is 87% sensitive and 92% specific for PJI, with an AUC of 0.94[29,30]. Calprotectin is less sensitive and specific than other synovial markers, including alpha-defensin, IL-6, and IL-8. However, it can be measured quantitatively by an inexpensive lateral flow assay that is already commonly used for other purposes in hospitals, so it may offer a relatively simple way to add information to the clinical picture.

**Synovial Fluid CRP (SF-CRP)**

Measurement of serum CRP has been a mainstay for PJI diagnosis, but slow-growing organisms and those that form a biofilm may not elevate serum CRP beyond the threshold for PJI diagnosis[31]. SF-CRP levels may be more accurate than serum CRP for diagnosing PJI[32,33]. A multiplex ELISA assay set to a diagnostic threshold of 3.7 mg/L had 84% sensitivity, 97% specificity, and an AUC of 0.91[32]. This SF-CRP assay slightly outperformed the serum CRP assay, with 76% sensitivity, 93% specificity, and an AUC of 0.88. When the study was repeated using the hospital laboratory assay for both serum and SF-CRP, a threshold of 9.5 mg/L was 85% sensitive and 95% specific and had an AUC of 0.92[33]. Another study observed that SF-CRP had an AUC of 0.96 for detecting chronic PJI of the hip, and that the addition of SF-CRP aided in making the diagnosis for 80% of the patients who had not met the criteria based on elevated serum markers[34].

Although these studies demonstrated that SF-CRP may outperform serum CRP, SF-CRP continues to lag behind synovial alpha-defensin, synovial IL-6, and synovial IL-8 in diagnostic accuracy. Moreover, one of the purposes of measuring serum CRP is to act as a screening test to determine which patients require SF aspiration for further testing; synovial CRP obviously cannot play a similar role.

**SF-IL-6 and SF-IL-8**

SF-IL-6 may be an accurate and helpful marker of PJI[13,15,35]. SF-IL-6 of >2.1 ng/mL is 86% specific and 59% sensitive for diagnosing PJI[13]. Deirmengian et al. showed that SF-IL-6 of >2.3 ng/mL is 97% specific for PJI, with an AUC of 0.95[15]. At SF-IL-6 values of >9.0 ng/mL, specificity approaches 100%[13]. When serum IL-6 is >2.6 pg/mL and SF-IL-6 is >2.1 ng/mL in the same patient, the PPV was 89%[13]. Since SF-IL-6 alone at a cutoff of 2.3 ng/mL is already fairly specific for PJI, we do not believe that the combination of serum and SF-IL-6 adds meaningful value to the diagnostic algorithm.

SF-IL-8 may be nearly as accurate for the diagnosis of PJI as alpha-defensin. In an analysis of SF from 95 patients, 29 of whom met MSIS criteria for PJI, a cutoff for SF-IL-8 of 6.5 ng/mL was 95% specific and 100% sensitive for diagnosing PJI[15]. A meta-analysis that included 3 studies examining SF-IL-8 showed slightly lower pooled specificity (94%) and sensitivity (87%)[36]. The inability of some laboratories to perform these tests, the relative expense involved, and a lack of a clear threshold has prevented these tests from entering clinical practice on a broader scale. With further studies focused on determining the appropriate threshold and overcoming some of the aforementioned limitations, these tests may gain future widespread use.

**Leukocyte Esterase (LE)**

LE is produced by activated neutrophils at the site of infection and therefore can be a marker of synovial leukocytosis and PJI. Synovial LE levels can be easily and quickly assessed using a urinalysis dipstick; results are categorized as negative, trace, +, or ++[37]. It is important to mention that a version of the LE strip that also provides a +++ read is available in Asia and other countries. Test strips producing a ++ result were 84% sensitive and 100% specific for knee PJI, with a PPV of 100% and negative predictive value (NPV) of 79%[38]. A meta-analysis demonstrated a pooled sensitivity of 81% and specificity of 97%, with ++ as the threshold[17]. The AUC was 0.97, indicating high accuracy[17].

Advantages of the LE test strip include ease of use, immediate results, and low cost[17]. A limitation is that a bloody aspirate affects test strip color and makes it difficult to interpret. This issue is resolved by centrifuging the sample prior to testing; however, this equipment may not be available or feasible for clinicians in the office setting. Furthermore, the sensitivity of the test is reduced, after samples are centrifuged, from 98% to 93%[39]. Thus, there is a need for a point-of-care test that can overcome the issue of blood-stained SF.

## The Clinical Need for a Diagnostic Alternative to ESR and CRP

ESR and CRP are often not elevated in PJI cases caused by slow-growing organisms, such as *Cutibacterium acnes,* that do not produce a suppurative host response[40]. This is of particular clinical concern in the setting of shoulder arthroplasty[41,42]. A review of 1,200 hip and knee revision arthroplasties demonstrated that ESR and CRP had higher false-negative rates than previously reported, particularly for slow-growing and culture-negative organisms[43]. Another group reported that 4% of confirmed PJI cases were seronegative, without ESR and CRP elevation[44].

ESR and CRP demonstrate temporal variations, complicating diagnosis of PJI and impacting the ability to use these tests to determine optimal timing of reimplantation. CRP levels peak at 2 to 3 days postoperatively, with normalization in one-third of patients after 3 weeks[45,46], but they can take approximately 3 months to return to baseline[47,48]. Serum ESR levels usually peak at postoperative day 5, and then gradually return to baseline over 90 days[48]. Surprisingly, 43% of patients do not follow the typical patterns described above, further illustrating the challenges with using ESR and CRP to diagnose and monitor PJI in the early perioperative period[48].

## Challenging Situations

Diagnosing PJI in the presence of ALTR[49-51], crystalline deposition arthropathy[52], systemic inflammatory disease[53], or steroid treatment[54] poses an even greater challenge[3,55]. These conditions often mimic PJI, and serum markers may be elevated.

To help distinguish aseptic failure from PJI in patients with ALTR, higher diagnostic thresholds have been proposed[56-59]. Since metallic debris can lead to errors in automated readings of SF-WBC and PMN differential, manual cell counts should be performed in cases of metallosis[50,60]. Alpha-defensin also has lower specificity and PPV in this setting[21,22]. LE test strips can be a valuable, inexpensive, and reliable intraoperative test for discerning PJI in the presence of ALTR[61,62], notwithstanding the limitations of this test when the specimen is blood-tinged after ALTR. Ultimately, a systematic and thorough preoperative evaluation for PJI is recommended in these patients—with possibly manual evaluation of the synovial WBC, PMN differential, and prolonged incubation of the SF for culture[60].

Inflammatory arthritis raises both systemic and intra-articular inflammatory markers, complicating PJI diagnosis using serum and synovial markers for infection[63]. In this setting, threshold values of 30 mm/hr for ESR and 17 mg/L for CRP had an AUC of 0.850 and 0.851, respectively[64]. Using thresholds of 29.5 mm/hr for ESR and 28 mg/L for CRP to diagnose persistent infection during 2-stage revision, the sensitivity and specificity was 64% and 77% for ESR, and 64% and 90% for CRP[65]. That said, a recent multicenter study of 1,220 patients suggested that the thresholds associated with PJI in patients with and without inflammatory arthritis were similar and resembled conventional cutoffs[53]. This contrast in the impact of rheumatologic disease on CRP and ESR thresholds seen in the historical compared with the more recent literature is likely a representation of modern management of inflammatory arthritis. Rheumatologists utilize CRP and ESR as measures of efficacy of biologic and disease-modifying treatments; thus, when one is evaluating a patient with well-controlled inflammatory arthritis for suspected PJI, the CRP and ESR thresholds become reliable. However, when inflammatory arthritis is not under control, caution is needed as these serum tests may be less reliable at the standard PJI cutoffs. The diagnostic utility of alpha-defensin may also be similarly affected by inflammatory arthritis[66-71].

Test results and clinical findings may be similarly confounded in crystalline deposition disease. Turbid, yellowish-white fluid suggestive of an inflammatory reaction in response to infection[72] may also be seen in noninfectious crystalline deposition diseases[73,74]. Alpha-defensin results can be influenced by crystal arthropathy, reducing its utility in this setting[75]. False-positive alpha-defensin lateral flow assays have been cited in the setting of acute gout[69].

## Culture-Negative PJI and Molecular Diagnostic Methods

Culture-negative infections are associated with increased diagnostic uncertainty. Several measures can be implemented to improve culture yield[76], including obtaining multiple samples, using separate sterile instruments for collection, expeditiously transferring samples to the laboratory, transporting SF in blood culture bottles, and prolonging culture incubation duration[76-79]. Despite these measures, culture-negative PJI rates have been reported to range between 5% and 42%[80-86]. Consequently, culture-independent molecular technologies have garnered interest for pathogen identification. Conventional and multiplex polymerase chain reaction (PCR)-based modalities have shown improved sensitivity for detecting

infective organisms in culture-negative cases; however, they are prone to false-positives and are limited by initial primer choice[87-89].

More recently, next-generation sequencing (NGS) has shown promise for detecting infective organisms in the research setting after orthopaedic infections. NGS refers to non-Sanger-based high-throughput DNA sequencing methods that produce massive amounts of genomic data, at reduced cost, in a shorter time, and with less manual intervention than prior methods[89]. Unlike PCR, NGS can be used in so-called open mode, which does not rely on a set of parameters or a panel of PCR primer targets. It is thus capable of characterizing all microbial DNA present within a sample by searching curated microbial databases that include bacteria, viruses, fungi, and parasites. Tarabichi et al. first demonstrated the utility of NGS by detecting *Streptococcus canis* in a patient with culture-negative PJI[90]. NGS has been useful for detecting organisms in 82% of culture-negative PJIs[91]. Furthermore, high concordance was found between SF NGS and culture[92].

Metagenomic shotgun sequencing can identify a wide range of PJI pathogens and may be particularly helpful in culture-negative PJI[93]. When metagenomic sequencing was used, "known pathogens" (confirmed by culture) were identified in 95% of culture-positive PJIs, and new "potential pathogens" (not identified by culture) were detected in 44% of culture-negative PJIs. Sequencing sonicated fluid from PJIs was 88% sensitive and 88% specific at the species level compared with pathogens identified on fluid culture[94].

While the clinical importance of microbial DNA detected by NGS is not yet certain, emerging data from prospective multicenter studies have suggested that PJI is polymicrobial at the DNA level in a majority of cases[95]. Data presented at the annual meeting of the American Association of Hip and Knee Surgeons in 2019 suggested that patients with PJI who eventually had treatment failure because of a new organism had that same infective organism isolated by NGS during the initial resection arthroplasty in 89% of failures[95].

However, the cost-effectiveness of molecular testing is undetermined. Current recommendations from the Infectious Diseases Society of America (IDSA) have suggested that NGS testing is justified when there is ongoing suspicion of infection, but conventional culture fails to confirm a diagnosis. Torchia et al. showed that NGS cost-effectiveness was dependent on a pretest probability of >70.0% and specificity of >94.1% in a Markov model projecting lifetime costs and quality-adjusted life years[96]. Further work in the form of multicenter randomized trials examining patient treatment outcomes will be necessary to validate the clinical diagnostic and therapeutic benefits of NGS and other molecular techniques in the setting of PJI.

## Overview

The nature of implant-related infections is complex. The infective organisms exist in the form of biofilm and may take refuge inside osteoblasts and bone canaliculi. Thus, reliance on culture to diagnose these infections is often inadequate. There currently is no absolute test for PJI diagnosis (Table I). Therefore, we recommend using the combination of tests described in the evidence-based and validated 2018 definition for PJI (Table III). While the new criteria and development of novel tests have helped to improve diagnostic accuracy, PJI diagnosis remains challenging and is in need of cost-effective innovations. ■

Amy S. Wasterlain, MD[1]
Karan Goswami, MD[1]
S. Ali Ghasemi, MD[1]
Javad Parvizi, MD, FRCS[1]

[1]Rothman Orthopaedic Institute at Thomas Jefferson University, Philadelphia, Pennsylvania

Email address for J. Parvizi: javadparvizi@gmail.com

ORCID iD for A.S. Wasterlain: 0000-0002-9635-1010
ORCID iD for K. Goswami: 0000-0003-0217-4752
ORCID iD for S.A. Ghasemi: 0000-0002-0746-9210
ORCID iD for J. Parvizi: 0000-0002-6985-5870

## References

**1.** Parvizi J, Zmistowski B, Berbari EF, Bauer TW, Springer BD, Della Valle CJ, Garvin KL, Mont MA, Wongworawat MD, Zalavras CG. New definition for periprosthetic joint infection: from the Workgroup of the Musculoskeletal Infection Society. Clin Orthop Relat Res. 2011 Nov;469(11):2992-4.

**2.** Workgroup Convened by the Musculoskeletal Infection Society. New definition for periprosthetic joint infection. J Arthroplasty. 2011 Dec;26(8):1136-8.

**3.** Parvizi J, Tan TL, Goswami K, Higuera C, Della Valle C, Chen AF, Shohat N. The 2018 definition of periprosthetic hip and knee infection: an evidence-based and validated criteria. J Arthroplasty. 2018 May;33(5):1309-1314.e2. Epub 2018 Feb 26.

**4.** Lee YS, Lee YK, Han SB, Nam CH, Parvizi J, Koo KH. Natural progress of D-dimer following total joint arthroplasty: a baseline for the diagnosis of the early postoperative infection. J Orthop Surg Res. 2018 Feb 13;13(1):36.

**5.** Schutgens REG, Haas FJLM, Gerritsen WBM, van der Horst F, Nieuwenhuis HK, Biesma DH. The usefulness of five D-dimer assays in the exclusion of deep venous thrombosis. J Thromb Haemost. 2003 May;1(5):976-81.

**6.** Kabrhel C, Mark Courtney D, Camargo CA Jr, Plewa MC, Nordenholz KE, Moore CL, Richman PB, Smithline HA, Beam DM, Kline JA. Factors associated with positive D-dimer results in patients evaluated for pulmonary embolism. Acad Emerg Med. 2010 Jun;17(6):589-97.

**7.** Shahi A, Kheir MM, Tarabichi M, Hosseinzadeh HRS, Tan TL, Parvizi J. Serum D-dimer test is promising for the diagnosis of periprosthetic joint infection and timing of reimplantation. J Bone Joint Surg Am. 2017 Sep 6; 99(17):1419-27.

**8.** Li R, Shao HY, Hao LB, Yu BZ, Qu PF, Zhou YX, Chen JY. Plasma fibrinogen exhibits better performance than plasma D-dimer in the diagnosis of periprosthetic joint infection: a multicenter retrospective study. J Bone Joint Surg Am. 2019 Apr 3; 101(7):613-9.

**9.** Davalos D, Akassoglou K. Fibrinogen as a key regulator of inflammation in disease. Semin Immunopathol. 2012 Jan;34(1):43-62. Epub 2011 Oct 31.

**10.** Klim SM, Amerstorfer F, Gruber G, Bernhardt GA, Radl R, Leitner L, Leithner A, Glehr M. Fibrinogen - a practical and cost efficient biomarker for detecting periprosthetic joint infection. Sci Rep. 2018 Jun 11;8(1):8802.

**11.** Di Cesare PE, Chang E, Preston CF, Liu CJ. Serum interleukin-6 as a marker of periprosthetic infection following total hip and knee arthroplasty. J Bone Joint Surg Am. 2005 Sep;87(9):1921-7.

**12.** Berbari E, Mabry T, Tsaras G, Spangehl M, Erwin PJ, Murad MH, Steckelberg J, Osmon D. Inflammatory blood laboratory levels as markers of prosthetic joint infection: a systematic review and meta-analysis. J Bone Joint Surg Am. 2010 Sep 1; 92(11):2102-9.

**13.** Randau TM, Friedrich MJ, Wimmer MD, Reichert B, Kuberra D, Stoffel-Wagner B, Limmer A, Wirtz DC, Gravius S. Interleukin-6 in serum and in synovial fluid enhances the differentiation between periprosthetic joint infection and aseptic loosening. PLoS One. 2014 Feb 21;9(2):e89045.

**14.** Zhao J, Zhang S, Zhang L, Dong X, Li J, Wang Y, Yao Y. Serum procalcitonin levels as a diagnostic marker for septic arthritis: a meta-analysis. Am J Emerg Med. 2017 Aug;35(8):1166-71. Epub 2017 Jun 7.

**15.** Deirmengian C, Kardos K, Kilmartin P, Cameron A, Schiller K, Parvizi J. Diagnosing periprosthetic joint infection: has the era of the biomarker arrived? Clin Orthop Relat Res. 2014 Nov;472(11):3254-62.

**16.** Bingham J, Clarke H, Spangehl M, Schwartz A, Beauchamp C, Goldberg B. The alpha defensin-1 biomarker assay can be used to evaluate the potentially infected total joint arthroplasty. Clin Orthop Relat Res. 2014 Dec;472(12):4006-9. Epub 2014 Sep 26.

**17.** Wyatt MC, Beswick AD, Kunutsor SK, Wilson MJ, Whitehouse MR, Blom AW. The alpha-defensin immunoassay and leukocyte esterase colorimetric strip test for the diagnosis of periprosthetic infection: a systematic review and meta-analysis. J Bone Joint Surg Am. 2016 Jun 15;98(12):992-1000.

**18.** Deirmengian C, Kardos K, Kilmartin P, Cameron A, Schiller K, Parvizi J. Combined measurement of synovial fluid α-defensin and C-reactive protein levels: highly accurate for diagnosing periprosthetic joint infection. J Bone Joint Surg Am. 2014 Sep 3;96(17):1439-45.

**19.** Shahi A, Parvizi J, Kazarian GS, Higuera C, Frangiamore S, Bingham J, Beauchamp C, Valle CD, Deirmengian C. The alpha-defensin test for periprosthetic joint infections is not affected by prior antibiotic administration. Clin Orthop Relat Res. 2016 Jul;474(7):1610-5.

**20.** Deirmengian C, Kardos K, Kilmartin P, Gulati S, Citrano P, Booth RE Jr. The alpha-defensin test for periprosthetic joint infection responds to a wide spectrum of organisms. Clin Orthop Relat Res. 2015 Jul;473(7):2229-35.

**21.** Kasparek MF, Kasparek M, Boettner F, Faschingbauer M, Hahne J, Dominkus M. Intraoperative diagnosis of periprosthetic joint infection using a novel alpha-defensin lateral flow assay. J Arthroplasty. 2016 Dec;31(12):2871-4. Epub 2016 May 27.

**22.** Okroj KT, Calkins TE, Kayupov E, Kheir MM, Bingham JS, Beauchamp CP, Parvizi J, Della Valle CJ. The alpha-defensin test for diagnosing periprosthetic joint infection in the setting of an adverse local tissue reaction secondary to a failed metal-on-metal bearing or corrosion at the head-neck junction. J Arthroplasty. 2018 Jun;33(6): 1896-8. Epub 2018 Jan 16.

**23.** American Academy of Orthopaedic Surgeons. Diagnosis and prevention of periprosthetic joint infections clinical practice guideline. 2019 Mar 11. Accessed 2020 Jan 24. https://www.aaos.org/pjiguideline

**24.** Renz N, Yermak K, Perka C, Trampuz A. Alpha defensin lateral flow test for diagnosis of periprosthetic joint infection: not a screening but a confirmatory test. J Bone Joint Surg Am. 2018 May 2;100(9):742-50.

**25.** Bauer TW, Bedair H, Creech JD, Deirmengian C, Eriksson H, Fillingham Y, Grigoryan G, Hickok N, Krenn V, Krenn V, Lazarinis S, Lidgren L, Lonner J, Odum S, Shah J, Shahi A, Shohat N, Tarabichi M, W-Dahl A, Wongworawat MD. Hip and knee section, diagnosis, laboratory tests: Proceedings of International Consensus on Orthopedic Infections. J Arthroplasty. 2019 Feb;34(2S):S351-9. Epub 2018 Oct 19.

**26.** Kelly MP, Darrith B, Hannon CP, Nam D, Courtney PM, Della Valle CJ. Synovial fluid alpha-defensin is an adjunctive tool in the equivocal diagnosis of periprosthetic joint infection. J Arthroplasty. 2018 Nov;33(11):3537-40. Epub 2018 Jun 28.

**27.** Ahmad SS, Hirschmann MT, Becker R, Shaker A, Ateschrang A, Keel MJB, Albers CE, Buetikofer L, Maqungo S, Stöckle U, Kohl S. A meta-analysis of synovial biomarkers in periprosthetic joint infection: Synovasure™ is less effective than the ELISA-based alpha-defensin test. Knee Surg Sports Traumatol Arthrosc. 2018 Oct; 26(10):3039-47. Epub 2018 Mar 20.

**28.** Eriksson HK, Nordström J, Gabrysch K, Hailer NP, Lazarinis S. Does the alpha-defensin immunoassay or the lateral flow test have better diagnostic value for periprosthetic joint infection? A meta-analysis. Clin Orthop Relat Res. 2018 May; 476(5):1065-72.

**29.** Wouthuyzen-Bakker M, Ploegmakers JJW, Kampinga GA, Wagenmakers-Huizenga L, Jutte PC, Muller Kobold AC. Synovial calprotectin: a potential biomarker to exclude a prosthetic joint infection. Bone Joint J. 2017 May;99-B(5):660-5.

**30.** Wouthuyzen-Bakker M, Ploegmakers JJW, Ottink K, Kampinga GA, Wagenmakers-Huizenga L, Jutte PC, Kobold ACM. Synovial calprotectin: an inexpensive biomarker to exclude a chronic prosthetic joint infection. J Arthroplasty. 2018 Apr; 33(4):1149-53. Epub 2017 Nov 13.

**31.** Johnson AJ, Zywiel MG, Stroh A, Marker DR, Mont MA. Serological markers can lead to false negative diagnoses of periprosthetic infections following total knee arthroplasty. Int Orthop. 2011 Nov;35(11):1621-6. Epub 2010 Dec 23.

**32.** Parvizi J, Jacovides C, Adeli B, Jung KA, Hozack WJ. Mark B. Coventry Award: synovial C-reactive protein: a prospective evaluation of a molecular marker for periprosthetic knee joint infection. Clin Orthop Relat Res. 2012 Jan;470(1):54-60.

**33.** Parvizi J, McKenzie JC, Cashman JP. Diagnosis of periprosthetic joint infection using synovial C-reactive protein. J Arthroplasty. 2012 Sep;27(8)(Suppl):12-6. Epub 2012 May 4.

**34.** Omar M, Ettinger M, Reichling M, Petri M, Guenther D, Gehrke T, Krettek C, Mommsen P. Synovial C-reactive protein as a marker for chronic periprosthetic infection in total hip arthroplasty. Bone Joint J. 2015 Feb;97-B(2):173-6.

**35.** Jacovides CL, Parvizi J, Adeli B, Jung KA. Molecular markers for diagnosis of periprosthetic joint infection. J Arthroplasty. 2011 Sep;26(6)(Suppl):99-103.e1. Epub 2011 May 13.

**36.** Lee YS, Koo KH, Kim HJ, Tian S, Kim TY, Maltenfort MG, Chen AF. Synovial fluid biomarkers for the diagnosis of periprosthetic joint infection: a systematic review and meta-analysis. J Bone Joint Surg Am. 2017 Dec 20;99(24):2077-84.

**37.** Parvizi J, Jacovides C, Antoci V, Ghanem E. Diagnosis of periprosthetic joint infection: the utility of a simple yet unappreciated enzyme. J Bone Joint Surg Am. 2011 Dec 21;93(24):2242-8.

**38.** Koh IJ, Han SB, In Y, Oh KJ, Lee DH, Kim TK; Knee Multicenter Collaboration Team. The leukocyte esterase strip test has practical value for diagnosing periprosthetic joint infection after total knee arthroplasty: a multicenter study. J Arthroplasty. 2017 Nov;32(11):3519-23. Epub 2017 Jun 12.

**39.** Li R, Lu Q, Zhou YG, Chai W, Lu SB, Chen JY. Centrifugation may change the results of leukocyte esterase strip testing in the diagnosis of periprosthetic joint infection. J Arthroplasty. 2018 Sep;33(9):2981-5. Epub 2018 Apr 19.

**40.** Pottinger P, Butler-Wu S, Neradilek MB, Merritt A, Bertelsen A, Jette JL, Warme WJ, Matsen FA 3rd. Prognostic factors for bacterial cultures positive for Propionibacterium acnes and other organisms in a large series of revision shoulder arthroplasties performed for stiffness, pain, or loosening. J Bone Joint Surg Am. 2012 Nov 21;94(22):2075-83.

**41.** Unter Ecker N, Koniker A, Gehrke T, Salber J, Zahar A, Hentschke M, Citak M. What is the diagnostic accuracy of alpha-defensin and leukocyte esterase test in periprosthetic shoulder infection? Clin Orthop Relat Res. 2019 Jul;477(7):1712-8.

**42.** Namdari S, Nicholson T, Abboud J, Lazarus M, Ramsey ML, Williams G, Parvizi J. *Cutibacterium acnes* is less commonly identified by next-generation sequencing than culture in primary shoulder surgery. J Shoulder Elbow Surg. Apr 2019;21:1-8.

**43.** Kheir MM, Tan TL, Shohat N, Foltz C, Parvizi J. Routine diagnostic tests for periprosthetic joint infection demonstrate a high false-negative rate and are influenced by the infecting organism. J Bone Joint Surg Am. 2018 Dec 5;100(23):2057-65.

**44.** McArthur BA, Abdel MP, Taunton MJ, Osmon DR, Hanssen AD. Seronegative infections in hip and knee arthroplasty: periprosthetic infections with normal erythrocyte sedimentation rate and C-reactive protein level. Bone Joint J. 2015 Jul;97-B(7):939-44.

**45.** Larsson S, Thelander U, Friberg S. C-reactive protein (CRP) levels after elective orthopedic surgery. Clin Orthop Relat Res. 1992 Feb;275:237-42.

**46.** Barretto JM, Loures FB, Albuquerque RS, Bezerra FD, Faro RV, Cavanellas NT. Evaluation of serum levels of C-reactive protein after total knee arthroplasty. Rev Bras Ortop. 2017 Mar 6;52(2):176-81.

**47.** Bilgen O, Atici T, Durak K, Karaeminoğullari O, Bilgen MS. C-reactive protein values and erythrocyte sedimentation rates after total hip and total knee arthroplasty. J Int Med Res. 2001 Jan-Feb;29(1):7-1.

**48.** Park KK, Kim TK, Chang CB, Yoon SW, Park KU. Normative temporal values of CRP and ESR in unilateral and staged bilateral TKA. Clin Orthop Relat Res. 2008 Jan; 466(1):179-88. Epub 2008 Jan 3.

**49.** Mikhael MM, Hanssen AD, Sierra RJ. Failure of metal-on-metal total hip arthroplasty mimicking hip infection. A report of two cases. J Bone Joint Surg Am. 2009 Feb;91(2):443-6.

**50.** Kwon YM, Fehring TK, Lombardi AV, Barnes CL, Cabanela ME, Jacobs JJ. Risk stratification algorithm for management of patients with dual modular taper total hip arthroplasty: consensus statement of the American Association of Hip and Knee Surgeons, the American Academy of Orthopaedic Surgeons and the Hip Society. J Arthroplasty. 2014 Nov;29(11):2060-4. Epub 2014 Jul 31.

**51.** Cooper HJ, Della Valle CJ, Berger RA, Tetreault M, Paprosky WG, Sporer SM, Jacobs JJ. Corrosion at the head-neck taper as a cause for adverse local tissue reactions after total hip arthroplasty. J Bone Joint Surg Am. 2012 Sep 19;94(18):1655-61.

**52.** Goswami K, Parvizi J, Maxwell Courtney P. Current recommendations for the diagnosis of acute and chronic PJI for hip and knee-cell counts, alpha-defensin, leukocyte esterase, next-generation sequencing. Curr Rev Musculoskelet Med. 2018 Sep;11(3):428-38.

**53.** Shohat N, Goswami K, Fillingham Y, Tan TL, Calkins T, Della Valle CJ, George J, Higuera C, Parvizi J. Diagnosing periprosthetic joint infection in inflammatory arthritis: assumption is the enemy of true understanding. J Arthroplasty. 2018 Nov; 33(11):3561-6. Epub 2018 Jul 24.

**54.** Azboy I, Bedair H, Demirtas A, Ford E Jr, Gahramanov A, Klement MR, Ploegmakers J, Schwarz E, Turkmen I. General assembly, prevention, risk mitigation, general factors: proceedings of International Consensus on Orthopedic Infections. J Arthroplasty. 2019 Feb;34(2S):S55-9. Epub 2018 Oct 19.

**55.** Shohat N, Bauer T, Buttaro M, Budhiparama N, Cashman J, Della Valle CJ, Drago L, Gehrke T, Marcelino Gomes LS, Goswami K, Hailer NP, Han SB, Higuera CA, Inaba Y, Jenny JY, Kjaersgaard-Andersen P, Lee M, Llinás A, Malizos K, Mont MA, Jones RM, Parvizi J, Peel T, Rivero-Boschert S, Segreti J, Soriano A, Sousa R, Spangehl M, Tan TL, Tikhilov R, Tuncay I, Winkler H, Witso E, Wouthuyzen-Bakker M,

Young S, Zhang X, Zhou Y, Zimmerli W. Hip and Knee Section, What is the definition of a periprosthetic joint infection (PJI) of the knee and the hip? Can the same criteria be used for both joints?: Proceedings of International Consensus on Orthopedic Infections. J Arthroplasty. 2019 Feb;34(2S):S325-7. Epub 2018 Oct 22.

**56.** Schinsky MF, Della Valle CJ, Sporer SM, Paprosky WG. Perioperative testing for joint infection in patients undergoing revision total hip arthroplasty. J Bone Joint Surg Am. 2008 Sep;90(9):1869-75.

**57.** Ghanem E, Antoci V Jr, Pulido L, Joshi A, Hozack W, Parvizi J. The use of receiver operating characteristics analysis in determining erythrocyte sedimentation rate and C-reactive protein levels in diagnosing periprosthetic infection prior to revision total hip arthroplasty. Int J Infect Dis. 2009 Nov;13(6):e444-9. Epub 2009 May 27.

**58.** Greidanus NV, Masri BA, Garbuz DS, Wilson SD, McAlinden MG, Xu M, Duncan CP. Use of erythrocyte sedimentation rate and C-reactive protein level to diagnose infection before revision total knee arthroplasty. A prospective evaluation. J Bone Joint Surg Am. 2007 Jul;89(7):1409-16.

**59.** Müller M, Morawietz L, Hasart O, Strube P, Perka C, Tohtz S. Diagnosis of periprosthetic infection following total hip arthroplasty—evaluation of the diagnostic values of pre- and intraoperative parameters and the associated strategy to preoperatively select patients with a high probability of joint infection. J Orthop Surg Res. 2008 Jul 21;3:31.

**60.** Yi PH, Cross MB, Moric M, Levine BR, Sporer SM, Paprosky WG, Jacobs JJ, Della Valle CJ. Do serologic and synovial tests help diagnose infection in revision hip arthroplasty with metal-on-metal bearings or corrosion? Clin Orthop Relat Res. 2015 Feb;473(2):498-505.

**61.** Tischler EH, Plummer DR, Chen AF, Della Valle CJ, Parvizi J. Leukocyte esterase: metal-on-metal failure and periprosthetic joint infection. J Arthroplasty. 2016 Oct; 31(10):2260-3. Epub 2016 Mar 15.

**62.** Wetters NG, Berend KR, Lombardi AV, Morris MJ, Tucker TL, Della Valle CJ. Leukocyte esterase reagent strips for the rapid diagnosis of periprosthetic joint infection. J Arthroplasty. 2012 Sep;27(8)(Suppl):8-11. Epub 2012 May 17.

**63.** Barrack R, Bhimani S, Blevins JL, Blevins K, Demetres M, Figgie M, Fillingham Y, Goodman S, Huddleston J, Kahlenberg C, Lautenbach C, Lin J, Lonner J, Lynch M, Malkani A, Martin L, Mirza S, Rahim Najjad MK, Penna S, Richardson S, Sculco P, Shahi A, Szymonifka J, Wang Q. General assembly, diagnosis, laboratory test: Proceedings of International Consensus on Orthopedic Infections. J Arthroplasty. 2019 Feb;34(2S):S187-95. Epub 2018 Oct 19.

**64.** Cipriano CA, Brown NM, Michael AM, Moric M, Sporer SM, Della Valle CJ. Serum and synovial fluid analysis for diagnosing chronic periprosthetic infection in patients with inflammatory arthritis. J Bone Joint Surg Am. 2012 Apr 4;94(7):594-600.

**65.** George J, Jawad M, Curtis GL, Samuel LT, Klika AK, Barsoum WK, Higuera CA. Utility of serological markers for detecting persistent infection in two-stage revision arthroplasty in patients with inflammatory arthritis. J Arthroplasty. 2018 Jul;33(7S): S205-8. Epub 2017 Dec 29.

**66.** Erdemli B, Özbek EA, Başarir K, Karahan ZC, Öcal D, Biriken D. Proinflammatory biomarkers' level and functional genetic polymorphisms in periprosthetic joint infection. Acta Orthop Traumatol Turc. 2018 Mar;52(2):143-7. Epub 2018 Jan 2.

**67.** Deirmengian C, Kardos K, Kilmartin P, Cameron A, Schiller K, Parvizi J. Combined measurement of synovial fluid α-defensin and C-reactive protein levels: highly accurate for diagnosing periprosthetic joint infection. J Bone Joint Surg Am. 2014 Sep 3;96(17):1439-45.

**68.** Bonanzinga T, Zahar A, Dütsch M, Lausmann C, Kendoff D, Gehrke T. How reliable is the alpha-defensin immunoassay test for diagnosing periprosthetic joint infection? A prospective study. Clin Orthop Relat Res. 2017 Feb;475(2):408-15.

**69.** Partridge DG, Gordon A, Townsend R. False-positive synovial fluid alpha-defensin test in a patient with acute gout affecting a prosthetic knee. Eur J Orthop Surg Traumatol. 2017 May;27(4):549-51. Epub 2017 Mar 17.

**70.** Frangiamore SJ, Gajewski ND, Saleh A, Farias-Kovac M, Barsoum WK, Higuera CA. α-defensin accuracy to diagnose periprosthetic joint infection-best available test? J Arthroplasty. 2016 Feb;31(2):456-60. Epub 2015 Sep 28.

**71.** Adams JR, Schwartz AJ. False-negative synovial alpha-defensin. Arthroplast Today. 2017 Jul 23;3(4):239-241.

**72.** Malech HL, Deleo FR, Quinn MT. The role of neutrophils in the immune system: an overview. Methods Mol Biol. 2014;1124:3-10.

**73.** Dougherty SH. Pathobiology of infection in prosthetic devices. Rev Infect Dis. 1988 Nov-Dec;10(6):1102-17.

**74.** Archibeck MJ, Rosenberg AG, Sheinkop MB, Berger RA, Jacobs JJ. Gout-induced arthropathy after total knee arthroplasty: a report of two cases. Clin Orthop Relat Res. 2001 Nov;392:377-82.

**75.** Plate A, Stadler L, Sutter R, Anagnostopoulos A, Frustaci D, Zbinden R, Fucentese SF, Zinkernagel AS, Zingg PO, Achermann Y. Inflammatory disorders mimicking periprosthetic joint infections may result in false-positive α-defensin. Clin Microbiol Infect. 2018 Nov;24(11):1212. Epub 2018 Mar 1.

**76.** Ascione T, Barrack R, Benito N, Blevins K, Brause B, Cornu O, Frommelt L, Gant V, Goswami K, Hu R, Klement MR, Komnos G, Malhotra R, Mirza Y, Munhoz Lima AL, Nelson C, Noor SS, O'Malley M, Oussedik S, Portillo ME, Prieto H, Saxena A, Sessa G. General assembly, diagnosis, pathogen isolation - culture matters: Proceedings of International Consensus on Orthopedic Infections. J Arthroplasty. 2019 Feb; 34(2S):S197-206. Epub 2018 Oct 22.

**77.** Renz N, Trampuz A. Periprothetische infektionen: aktueller stand der diagnostik und therapie. Orthop Rheumatol. 2015 Dec;18(6):20-8.

**78.** Trampuz A, Piper KE, Jacobson MJ, Hanssen AD, Unni KK, Osmon DR, Mandrekar JN, Cockerill FR, Steckelberg JM, Greenleaf JF, Patel R. Sonication of removed hip and knee prostheses for diagnosis of infection. N Engl J Med. 2007 Aug 16; 357(7):654-63.

**79.** Bémer P, Léger J, Tandé D, Plouzeau C, Valentin AS, Jolivet-Gougeon A, Lemarié C, Kempf M, Héry-Arnaud G, Bret L, Juvin ME, Giraudeau B, Corvec S, Burucoa C; Centre de Référence des Infections Ostéo-articulaires du Grand Ouest (CRIOGO) Study Team. How many samples and how many culture media to diagnose a prosthetic joint infection: a clinical and microbiological prospective multicenter study. J Clin Microbiol. 2016 Feb;54(2):385-91. Epub 2015 Dec .

**80.** Ibrahim MS, Twaij H, Haddad FS. Two-stage revision for the culture-negative infected total hip arthroplasty: a comparative study. Bone Joint J. 2018 Jan;100-B(1)(Supple A):3-8.

**81.** Kim YH, Kulkarni SS, Park JW, Kim JS, Oh HK, Rastogi D. Comparison of infection control rates and clinical outcomes in culture-positive and culture-negative infected total-knee arthroplasty. J Orthop. 2015 Feb 17;12(Suppl 1):S37-43.

**82.** Li H, Ni M, Li X, Zhang Q, Li X, Chen J. Two-stage revisions for culture-negative infected total knee arthroplasties: a five-year outcome in comparison with one-stage and two-stage revisions for culture-positive cases. J Orthop Sci. 2017 Mar;22(2): 306-12. Epub 2016 Dec 18.

**83.** Malekzadeh D, Osmon DR, Lahr BD, Hanssen AD, Berbari EF. Prior use of antimicrobial therapy is a risk factor for culture-negative prosthetic joint infection. Clin Orthop Relat Res. 2010 Aug;468(8):2039-45.

**84.** Berbari EF, Marculescu C, Sia I, Lahr BD, Hanssen AD, Steckelberg JM, Gullerud R, Osmon DR. Culture-negative prosthetic joint infection. Clin Infect Dis. 2007 Nov 1; 45(9):1113-9. Epub 2007 Sep 26.

**85.** Choi HR, Kwon YM, Freiberg AA, Nelson SB, Malchau H. Periprosthetic joint infection with negative culture results: clinical characteristics and treatment outcome. J Arthroplasty. 2013 Jun;28(6):899-903. Epub 2013 Mar 20.

**86.** Huang R, Hu CC, Adeli B, Mortazavi J, Parvizi J. Culture-negative periprosthetic joint infection does not preclude infection control. Clin Orthop Relat Res. 2012 Oct; 470(10):2717-23.

**87.** Gomez E, Cazanave C, Cunningham SA, Greenwood-Quaintance KE, Steckelberg JM, Uhl JR, Hanssen AD, Karau MJ, Schmidt SM, Osmon DR, Berbari EF, Mandrekar J, Patel R. Prosthetic joint infection diagnosis using broad-range PCR of biofilms dislodged from knee and hip arthroplasty surfaces using sonication. J Clin Microbiol. 2012 Nov;50(11):3501-8. Epub 2012 Aug 15.

**88.** Bergin PF, Doppelt JD, Hamilton WG, Mirick GE, Jones AE, Sritulanondha S, Helm JM, Tuan RS. Detection of periprosthetic infections with use of ribosomal RNA-based polymerase chain reaction. J Bone Joint Surg Am. 2010 Mar;92(3):654-63.

**89.** Goldberg B, Sichtig H, Geyer C, Ledeboer N, Weinstock GM. Making the leap from research laboratory to clinic: challenges and opportunities for next-generation sequencing in infectious disease diagnostics. mBio. 2015 Dec 8;6(6):e01888-15.

**90.** Tarabichi M, Alvand A, Shohat N, Goswami K, Parvizi J. Diagnosis of *Streptococcus canis* periprosthetic joint infection: the utility of next-generation sequencing. Arthroplast Today. 2017 Nov 3;4(1):20-3.

**91.** Tarabichi M, Shohat N, Goswami K, Alvand A, Silibovsky R, Belden K, Parvizi J. Diagnosis of periprosthetic joint infection: the potential of next-generation sequencing. J Bone Joint Surg Am. 2018 Jan 17;100(2):147-54.

**92.** Tarabichi M, Shohat N, Goswami K, Parvizi J. Can next generation sequencing play a role in detecting pathogens in synovial fluid? Bone Joint J. 2018 Feb;100-B(2): 127-33.

**93.** Thoendel MJ, Jeraldo PR, Greenwood-Quaintance KE, Yao JZ, Chia N, Hanssen AD, Abdel MP, Patel R. Identification of prosthetic joint infection pathogens using a shotgun metagenomics approach. Clin Infect Dis. 2018 Oct 15;67(9):1333-8.

**94.** Street TL, Sanderson ND, Atkins BL, Brent AJ, Cole K, Foster D, McNally MA, Oakley S, Peto L, Taylor A, Peto TEA, Crook DW, Eyre DW. Molecular diagnosis of orthopaedic device-related infection direct from sonication fluid by metagenomic sequencing. J Clin Microbiol. 2017 Aug;55(8):2334-47. Epub 2017 May 10.

**95.** Goswami K, Higuera CA, Smith EL, Malkani AL, Palumbo BT, Klatt BA, Goyal N, Pelt C, Palumbo B, Minter J, Lee GC, Prieto H, Nam D, Levine B, Bini S, Hansen E, Cross MB, Della Valle CJ, Parvizi J. Reinfection or persistence of periprosthetic joint infection? Next generation sequencing reveals new findings. Read at the Annual Meeting of the American Association of Hip and Knee Surgeons; 2019 Nov 1-4; Dallas, TX. Paper no. 31.

**96.** Torchia MT, Austin DC, Kunkel ST, Dwyer KW, Moschetti WE. Next-generation sequencing vs culture-based methods for diagnosing periprosthetic joint infection after total knee arthroplasty: a cost-effectiveness analysis. J Arthroplasty. 2019 Jul; 34(7):1333-41. Epub 2019 Mar 19.

**97.** Osmon DR, Berbari EF, Berendt AR, Lew D, Zimmerli W, Steckelberg JM, Rao N, Hanssen A, Wilson WR, Infectious Diseases Society of America. Diagnosis and management of prosthetic joint infection: clinical practice guidelines by the Infectious Diseases Society of America. Clin Infect Dis. 2013;56(1):e1-e25.

**98.** Parvizi J, Gehrke T; International Consensus Group on Periprosthetic Joint Infection. Definition of periprosthetic joint infection. J Arthroplasty. 2014 Jul;29(7):1331.